

(Pees-) Letsel van de Schouder



Eindhoven 2 mei 2018



FocusKliniek
Orthopedie

Bronovo
Westeinde
Antoniushove

Peer van der Zwaal MD PhD

Orthopedisch chirurg - Traumachirurg

Interactief



Letsel = Trauma



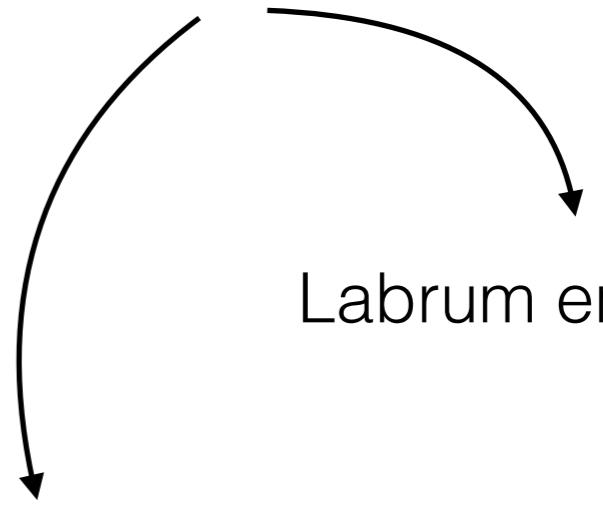
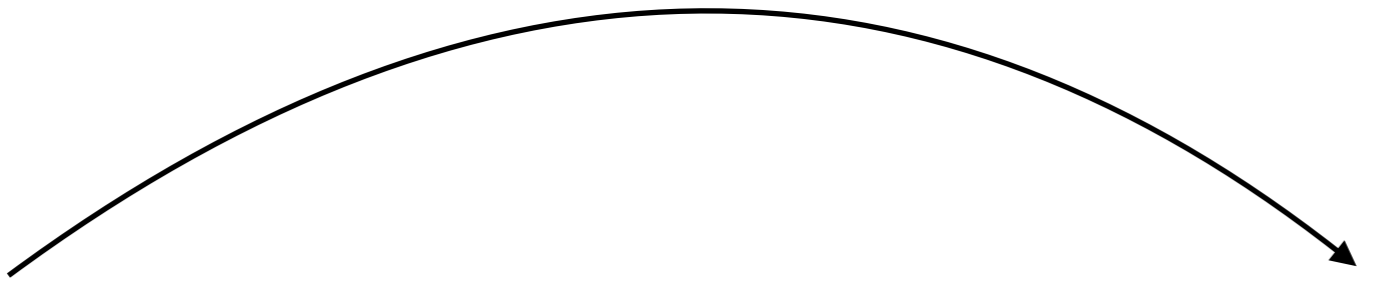
Anatomie

Specifieke letsels

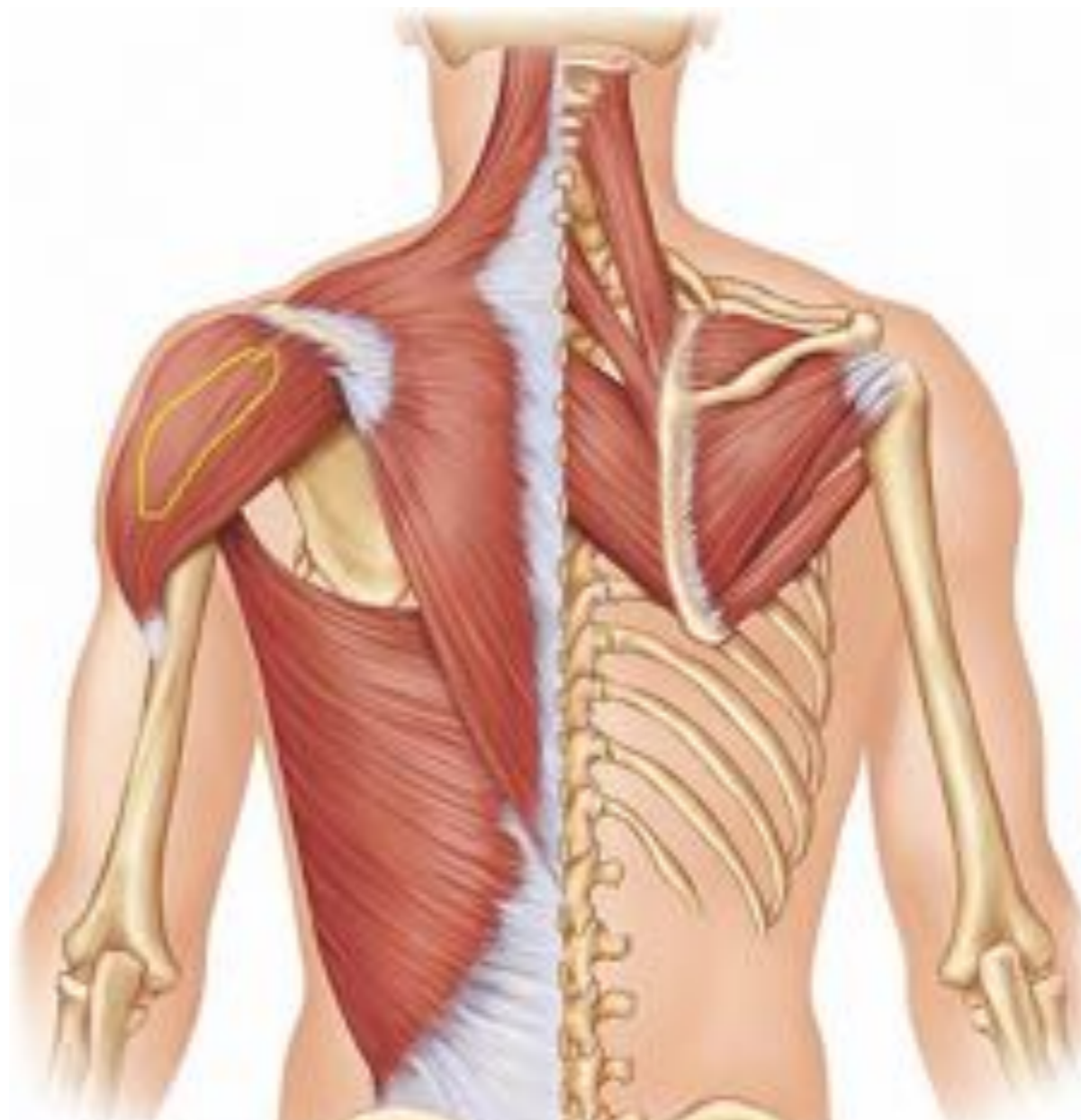Labrum en kapsel

Minder voorkomende letsels

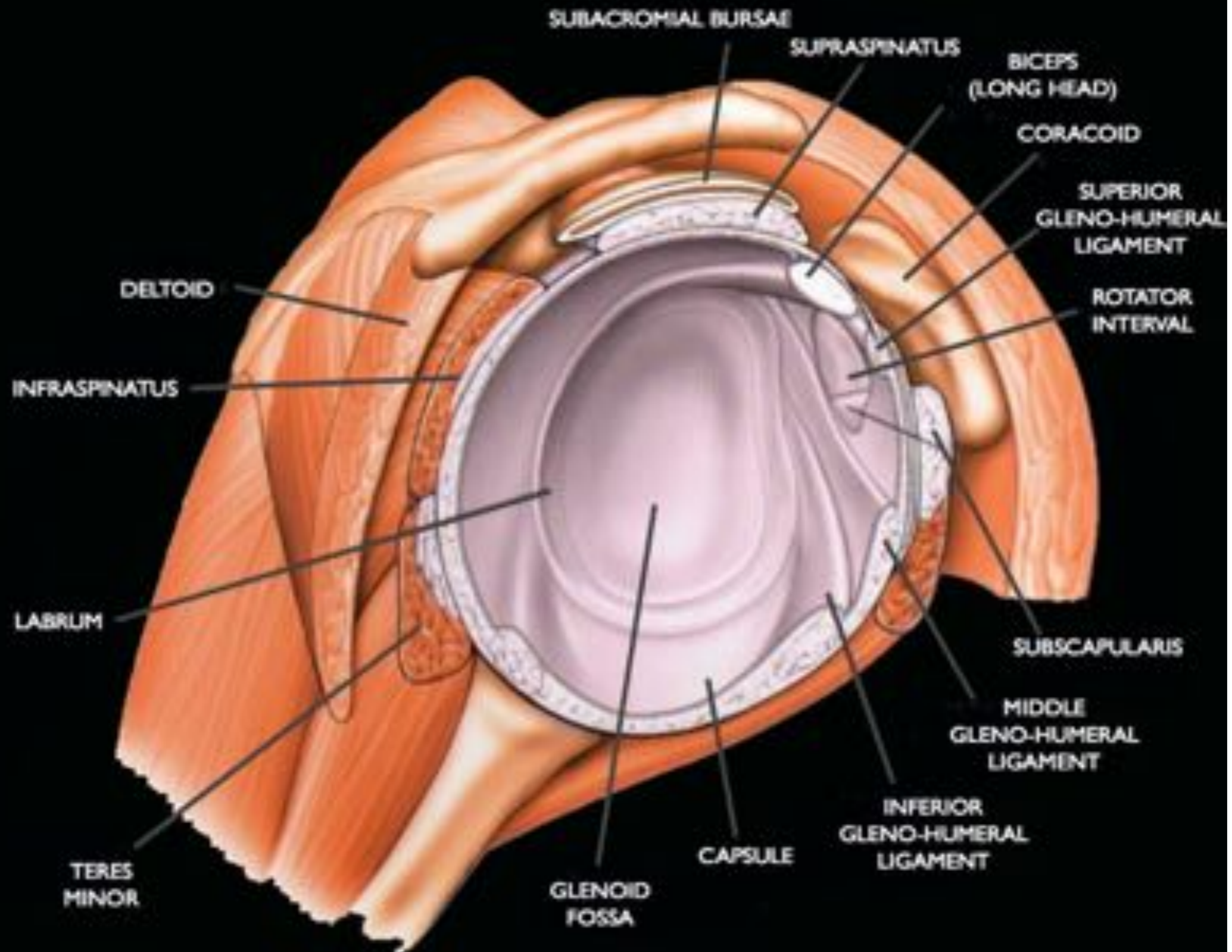
Casus



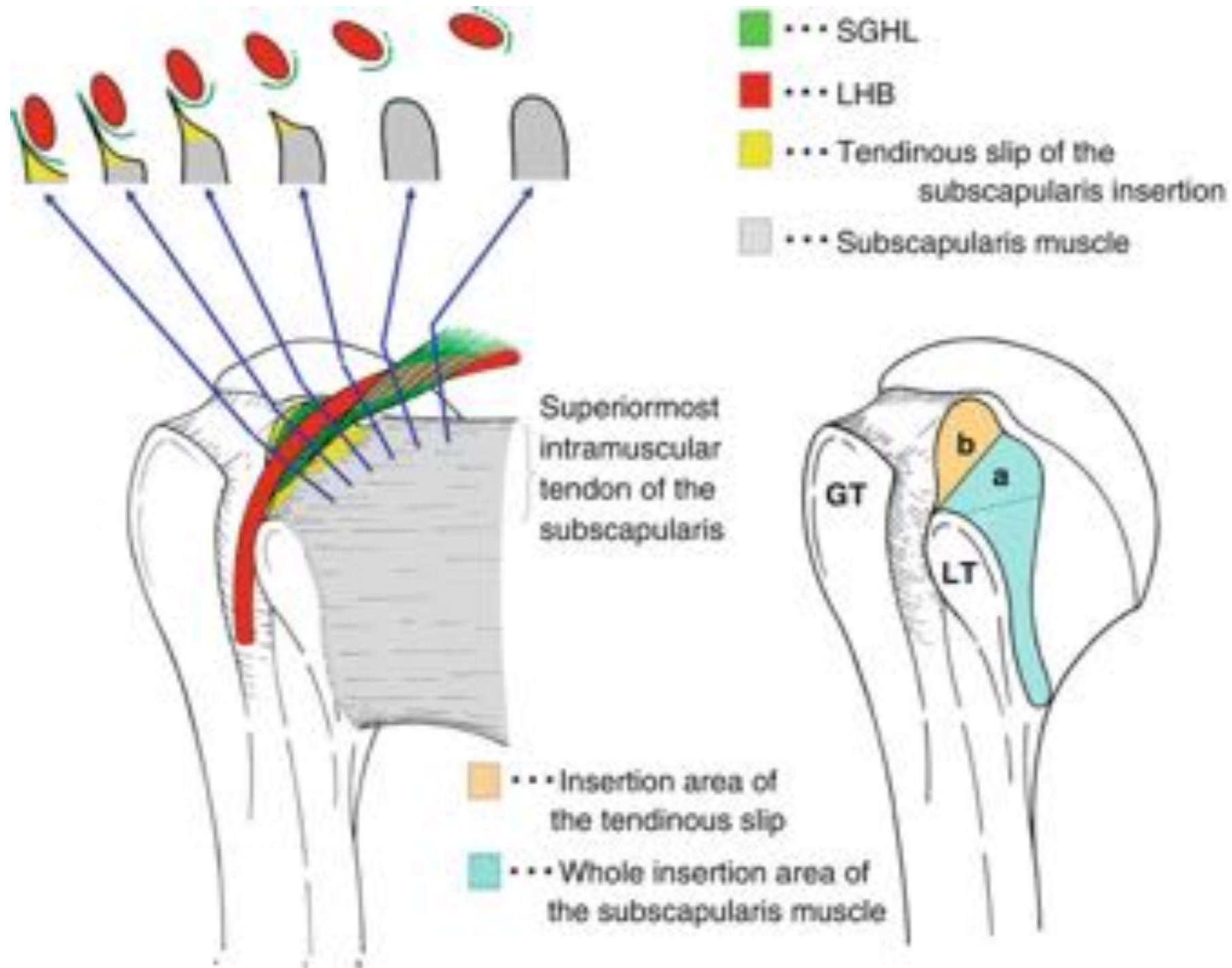
Anatomie, maar niet dit....



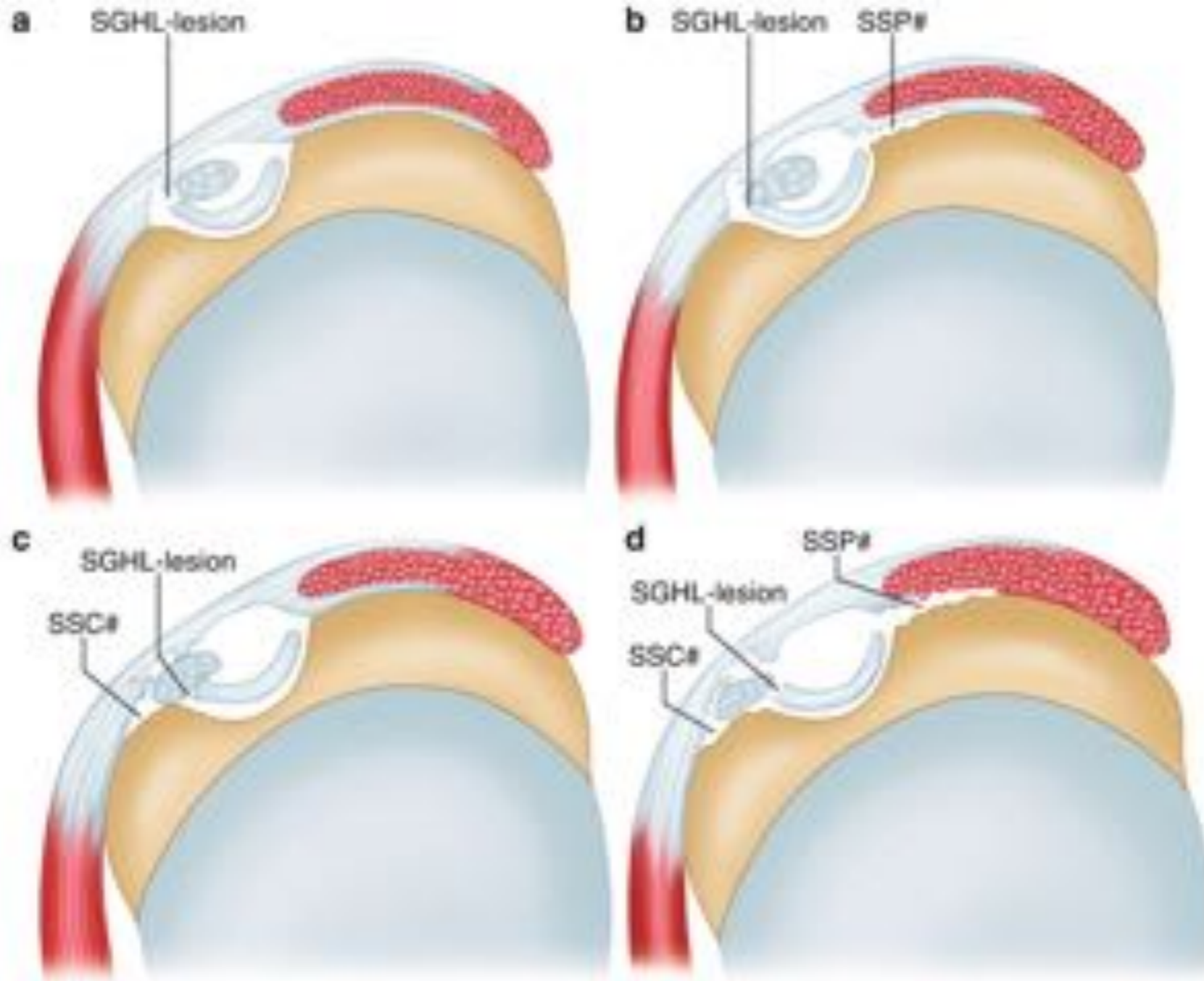
Intra-articulaire anatomie



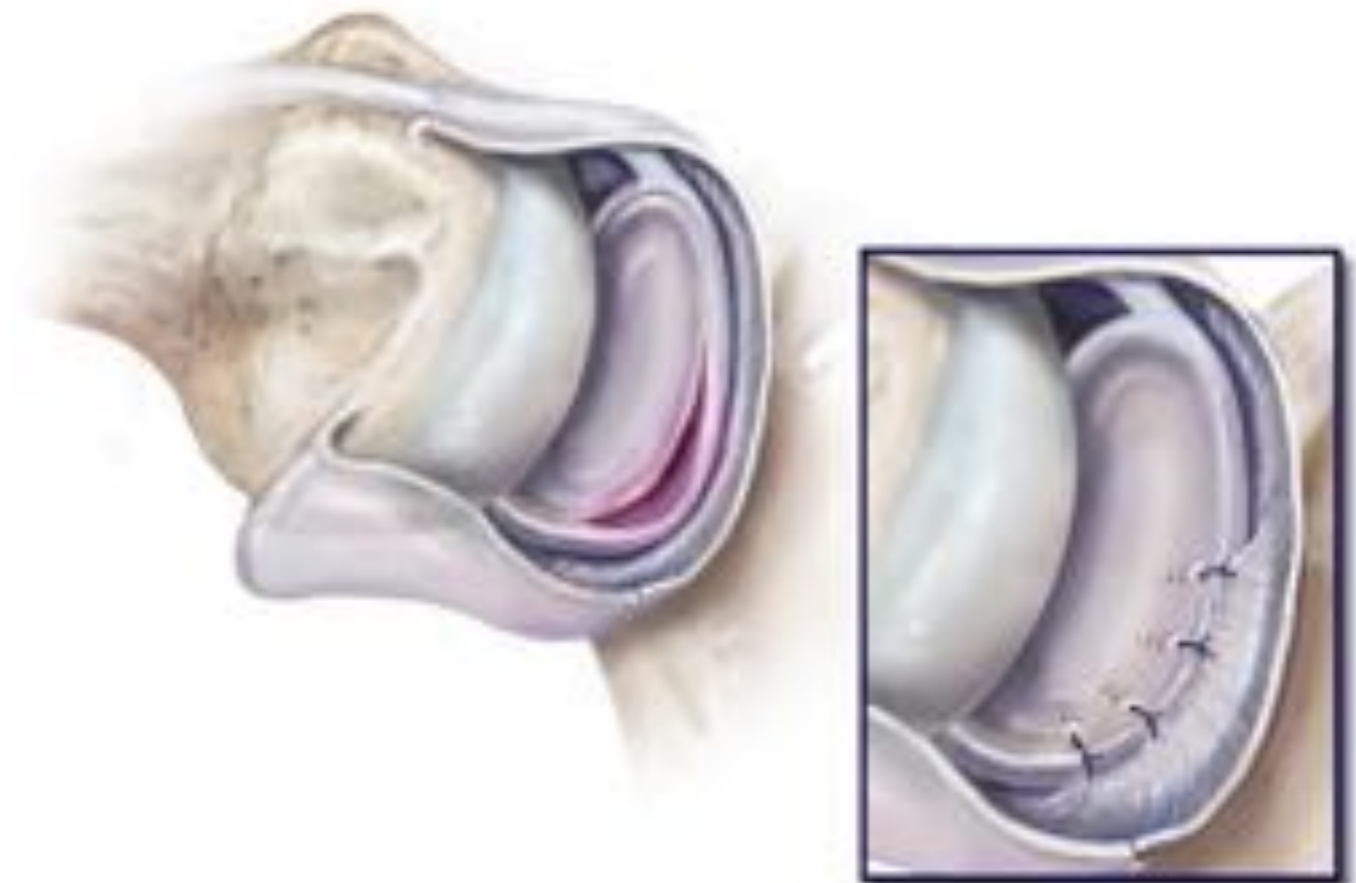
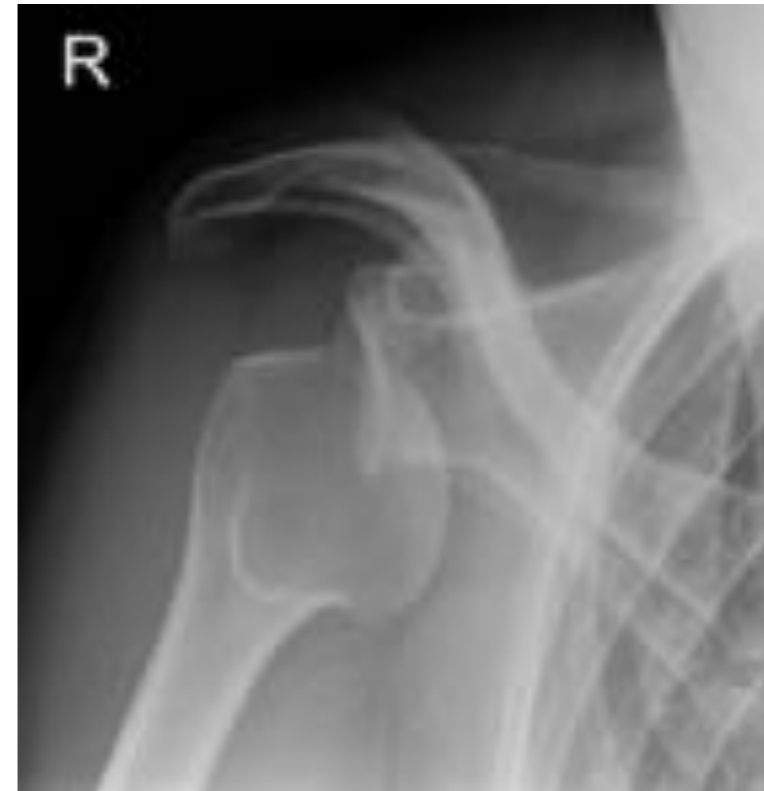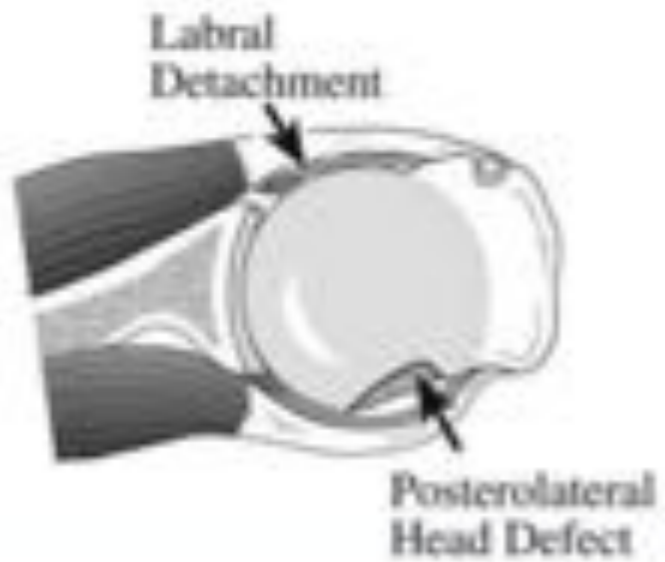
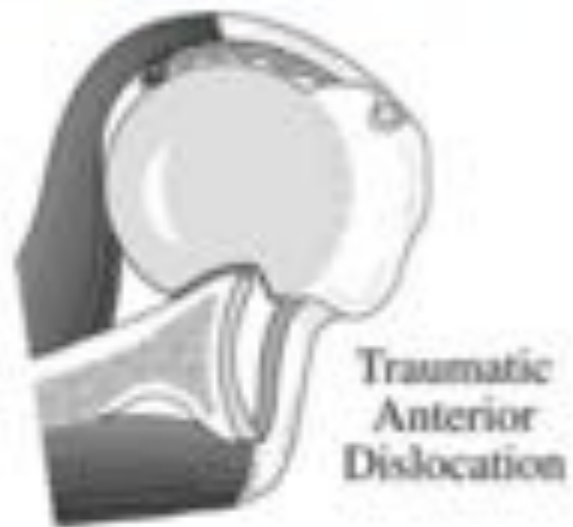
Biceps (-pulley) anatomie



Biceps (-pulley) leasie

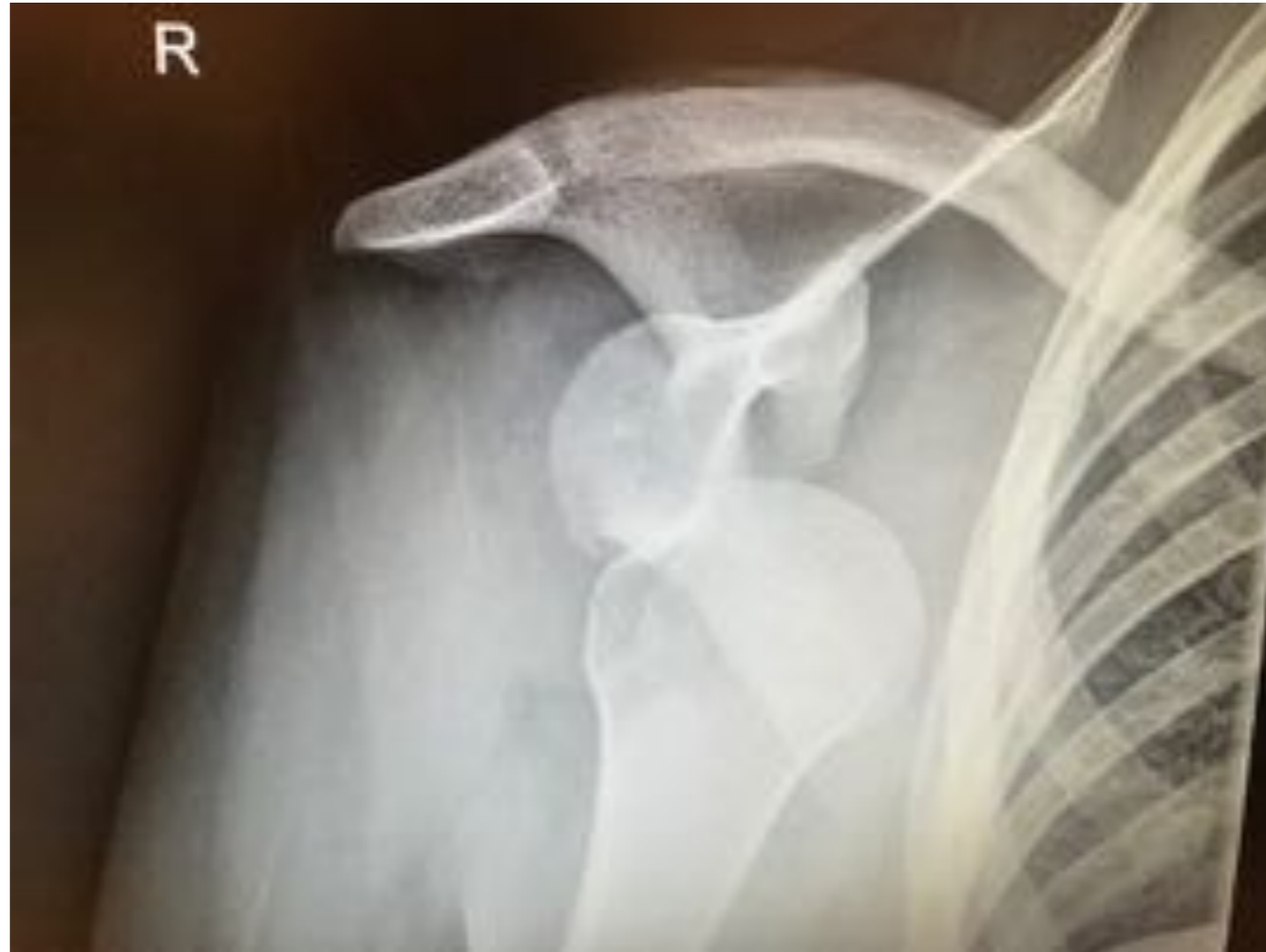

Anterieure schouderluxatie



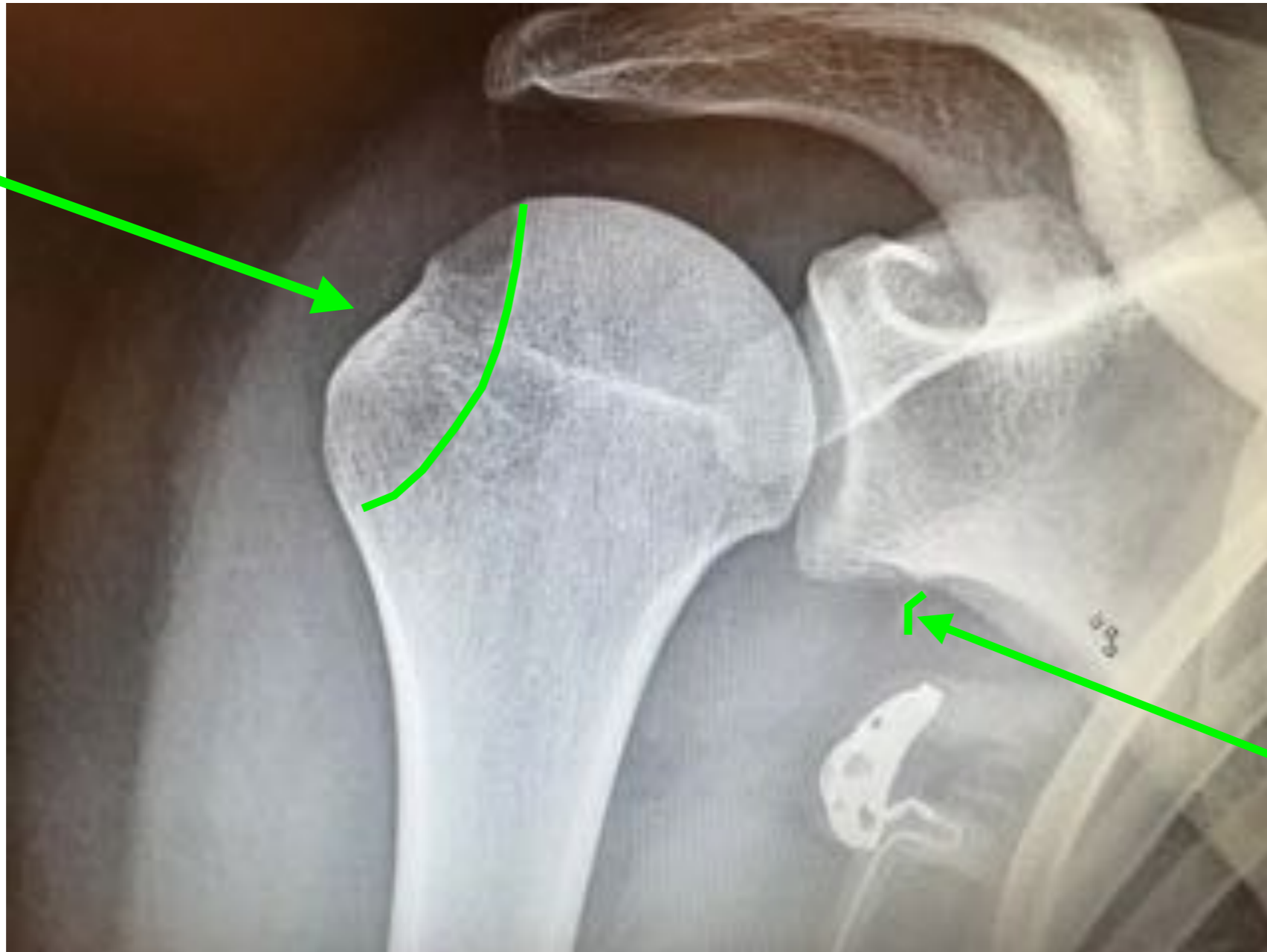
Antero-inferieure schouderluxatie

Röntgen foto



Bevindingen na repositie?

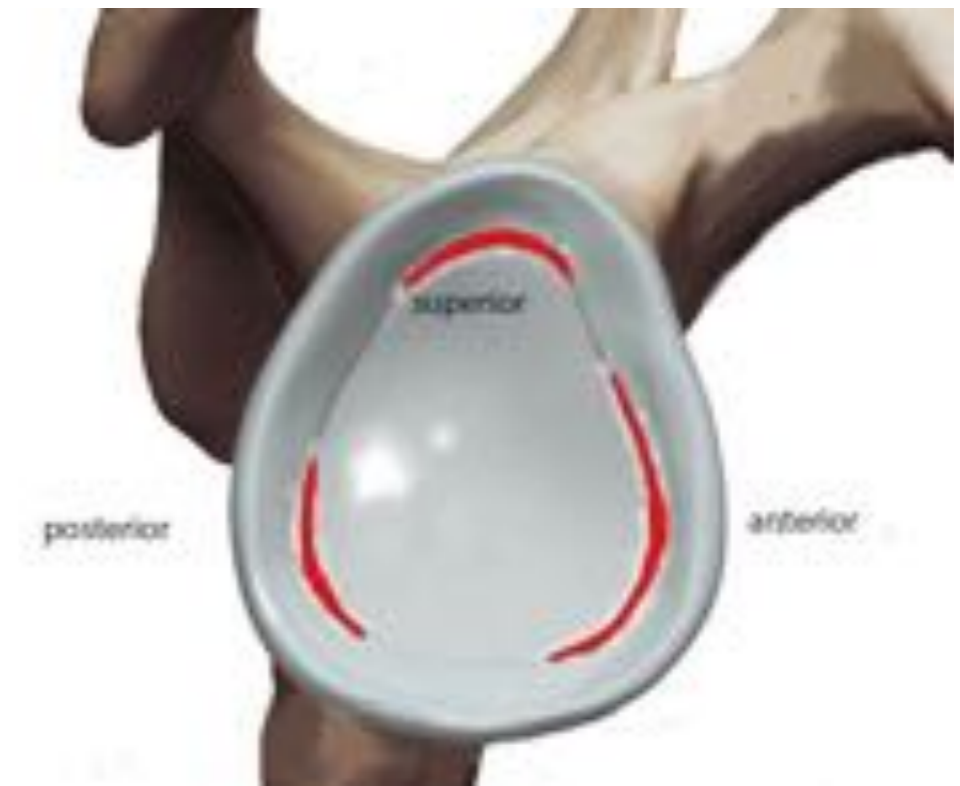Hill-Sachs
Impression



Bony
Bankart

AbEr laesies (luxaties)

- Bankart en partieel cuff letsel
- 360 graden labrum glenoidale



Direct trauma

Pijn
“Knap”

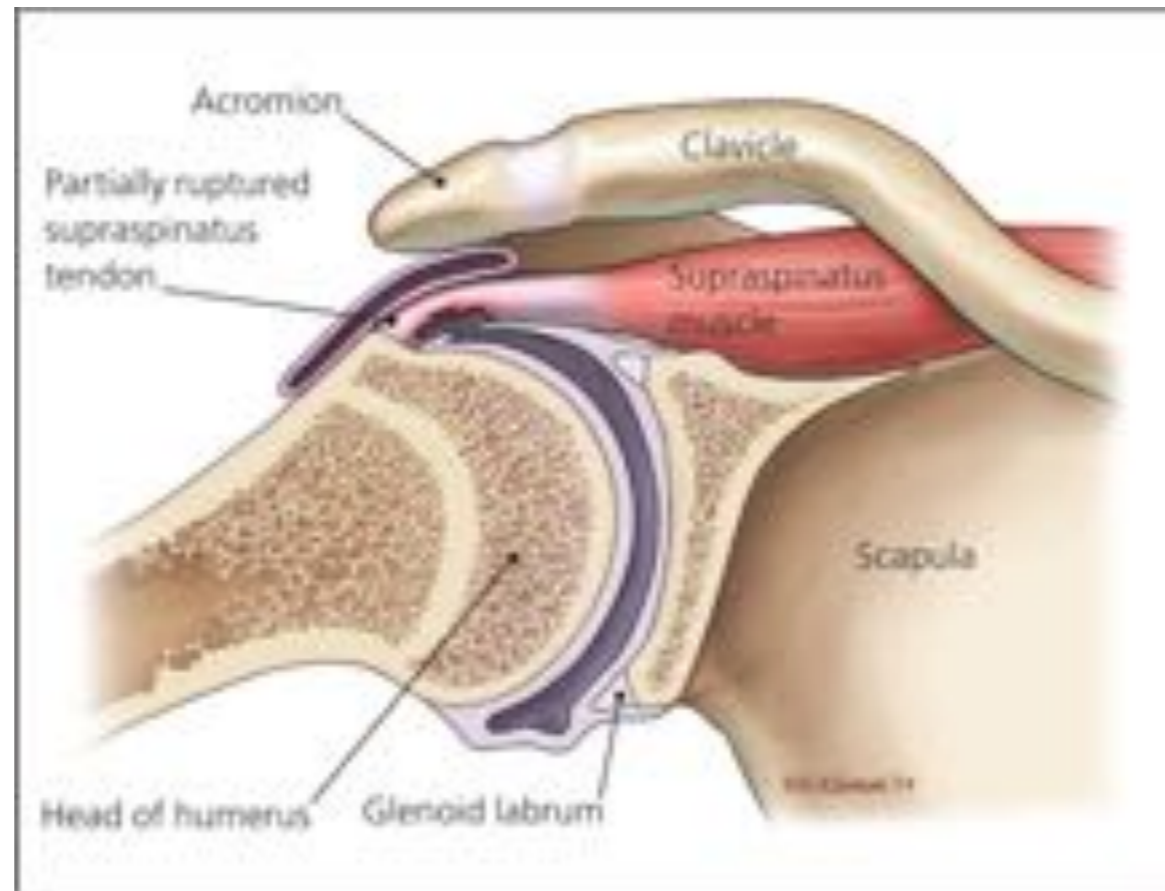
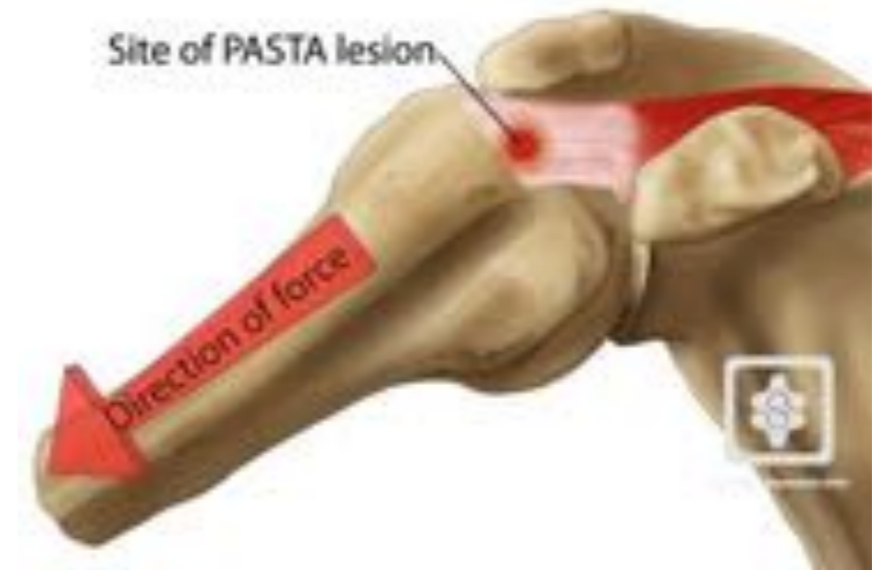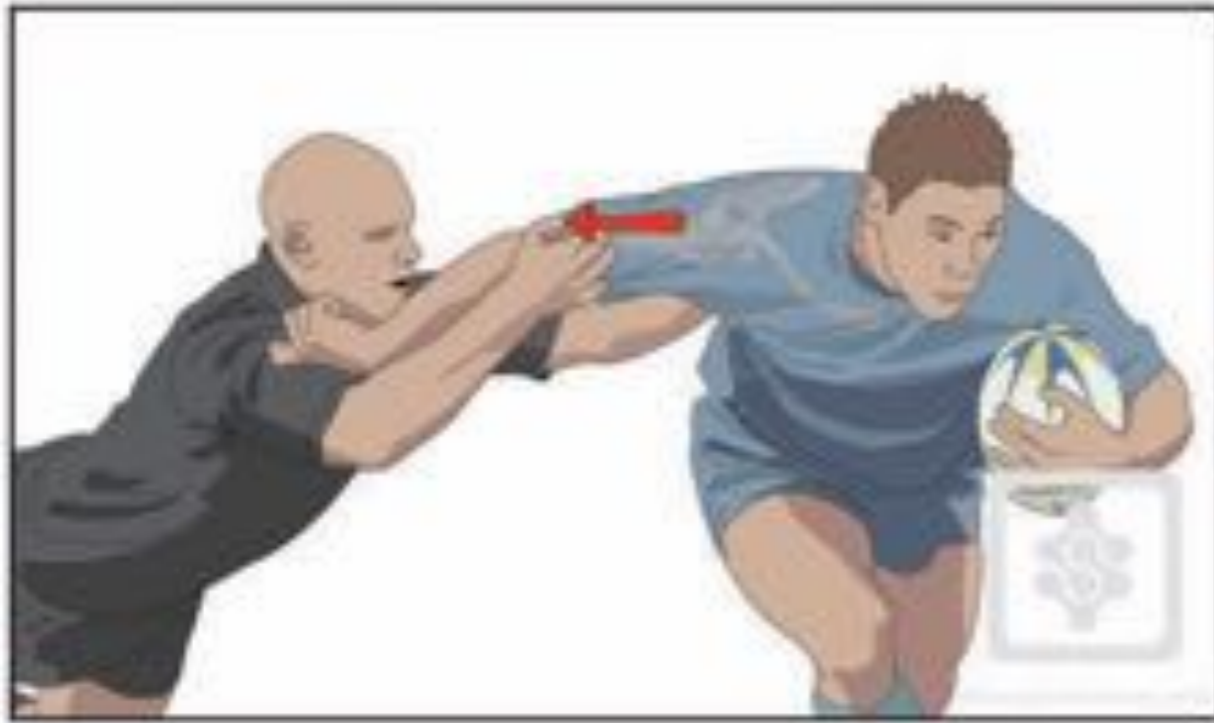Dead arm fenomeen
Niet meer verder spelen

-SLAP
-Posterior labrum



PASTA lesion

Partial Articular Supraspinatus Tendon Avulsion

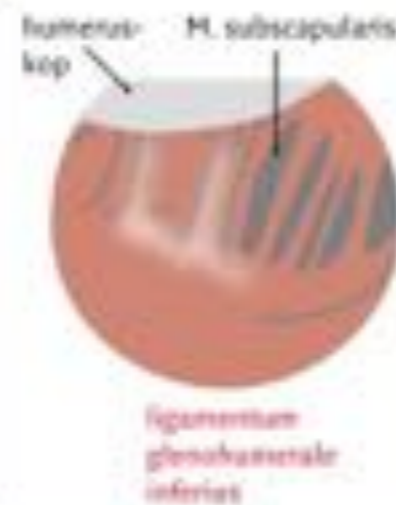
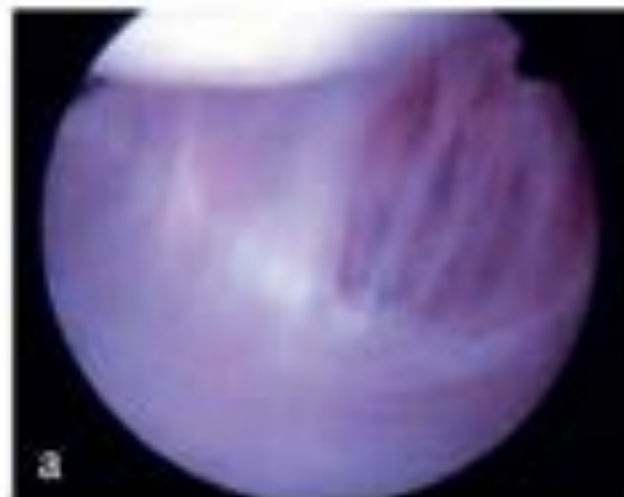
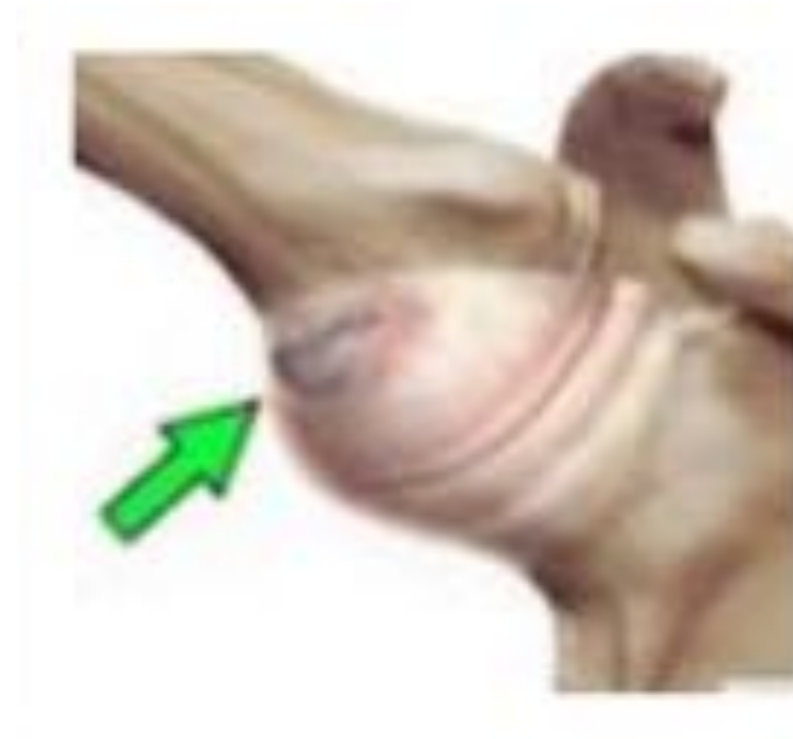
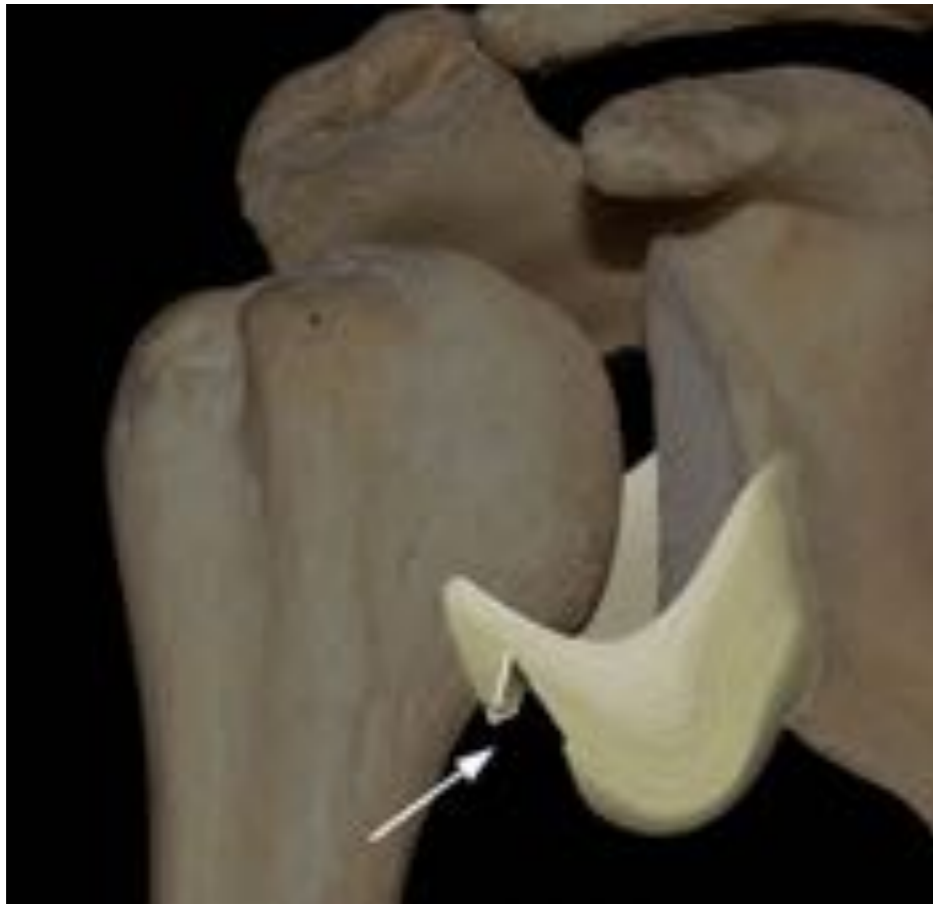
Try Score Injury



HAGL

Humeral Avulsion Glenohumeral Ligament

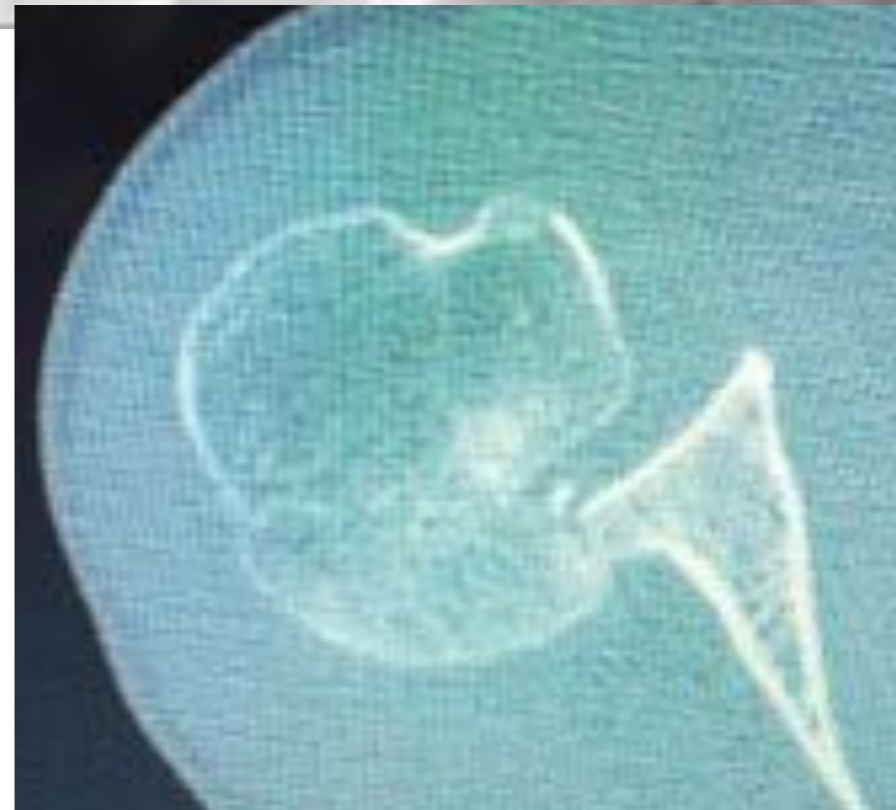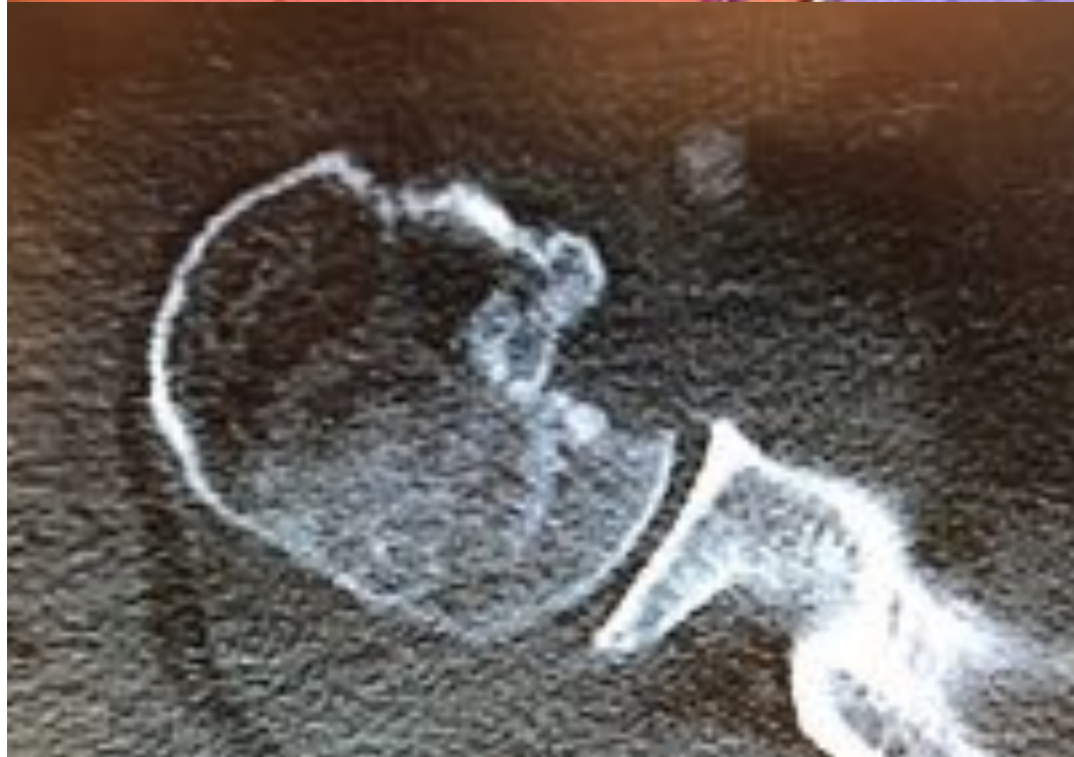

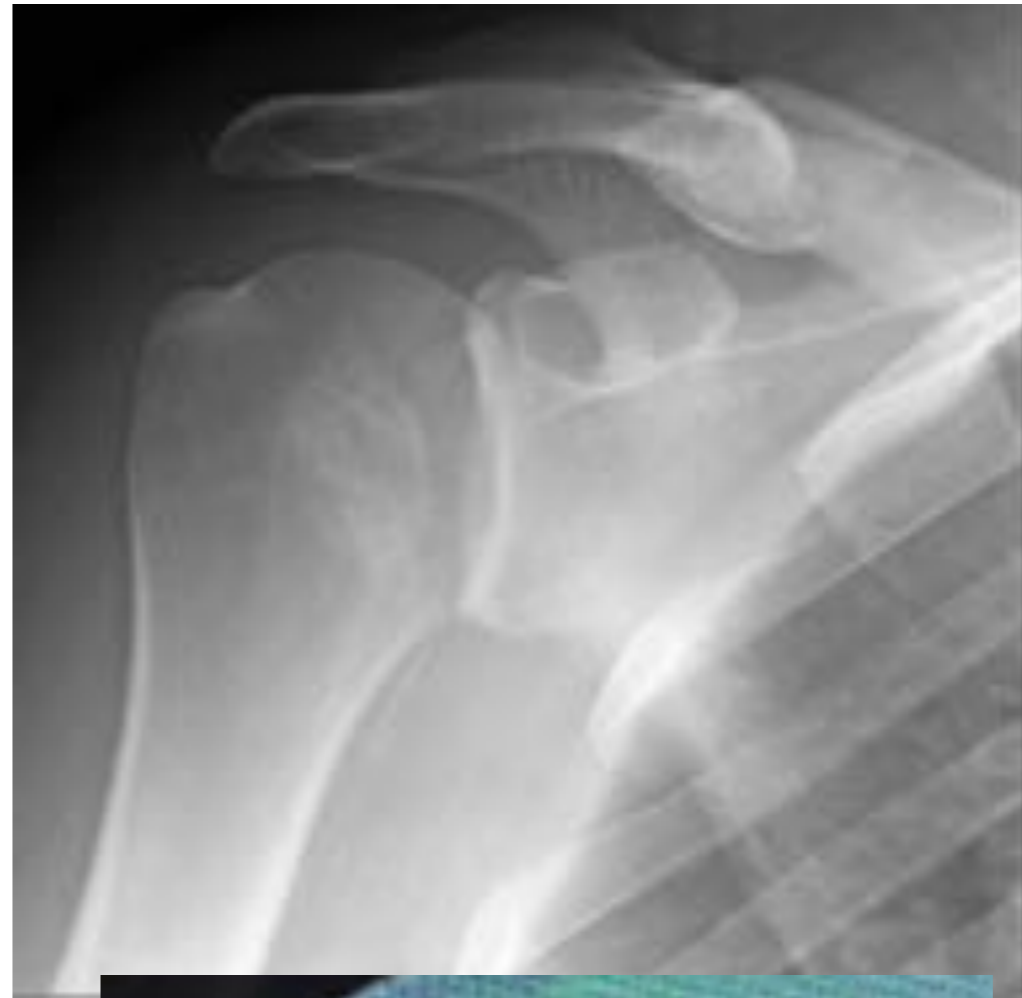
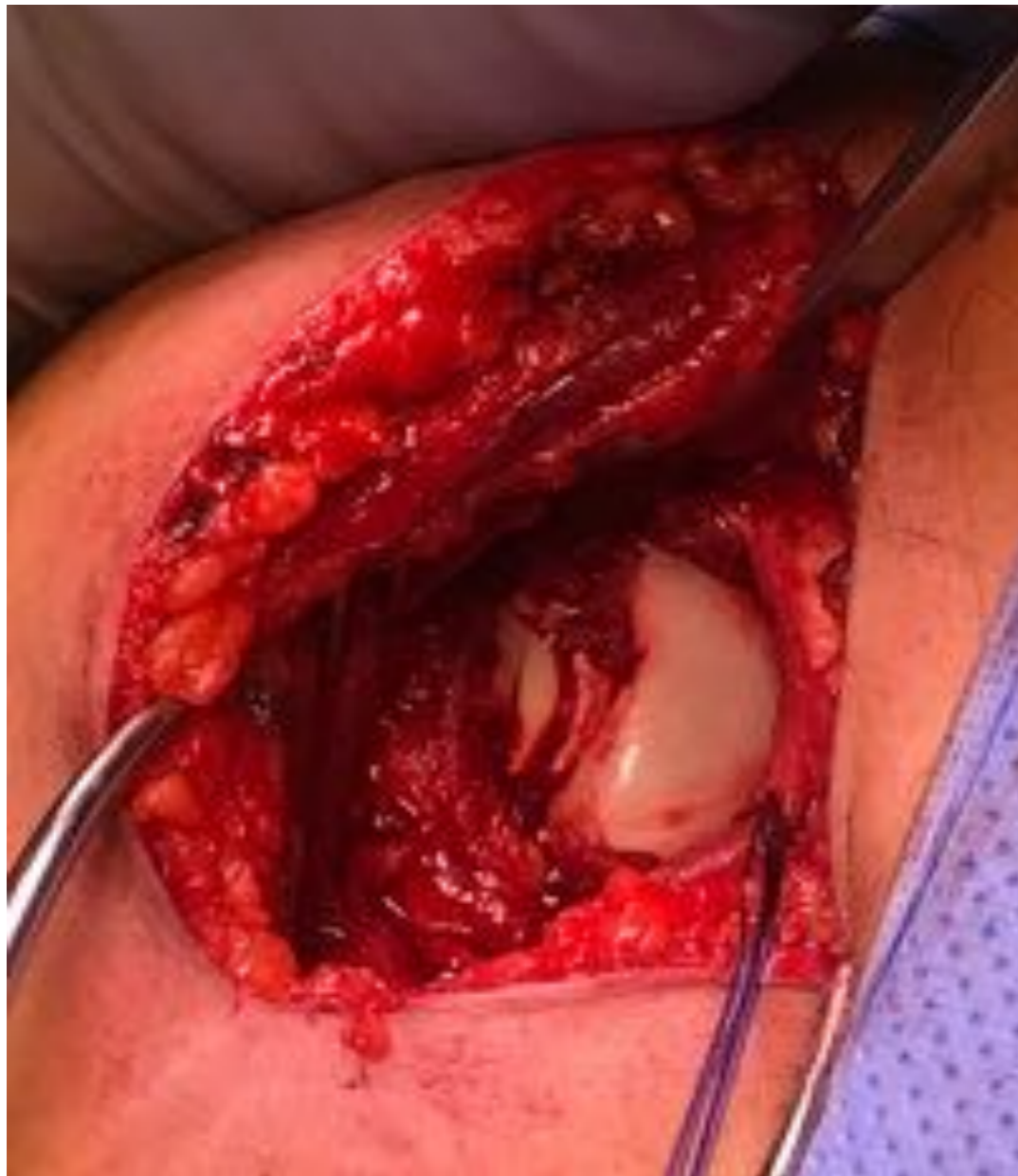Letselverdeling: mechanisme vs locatie

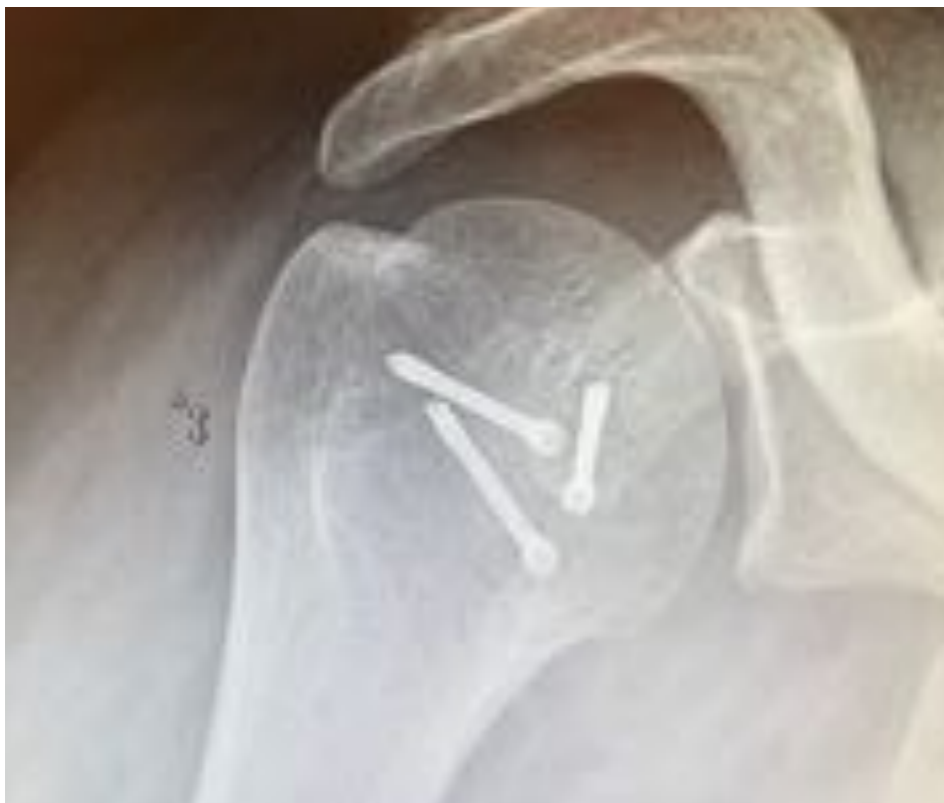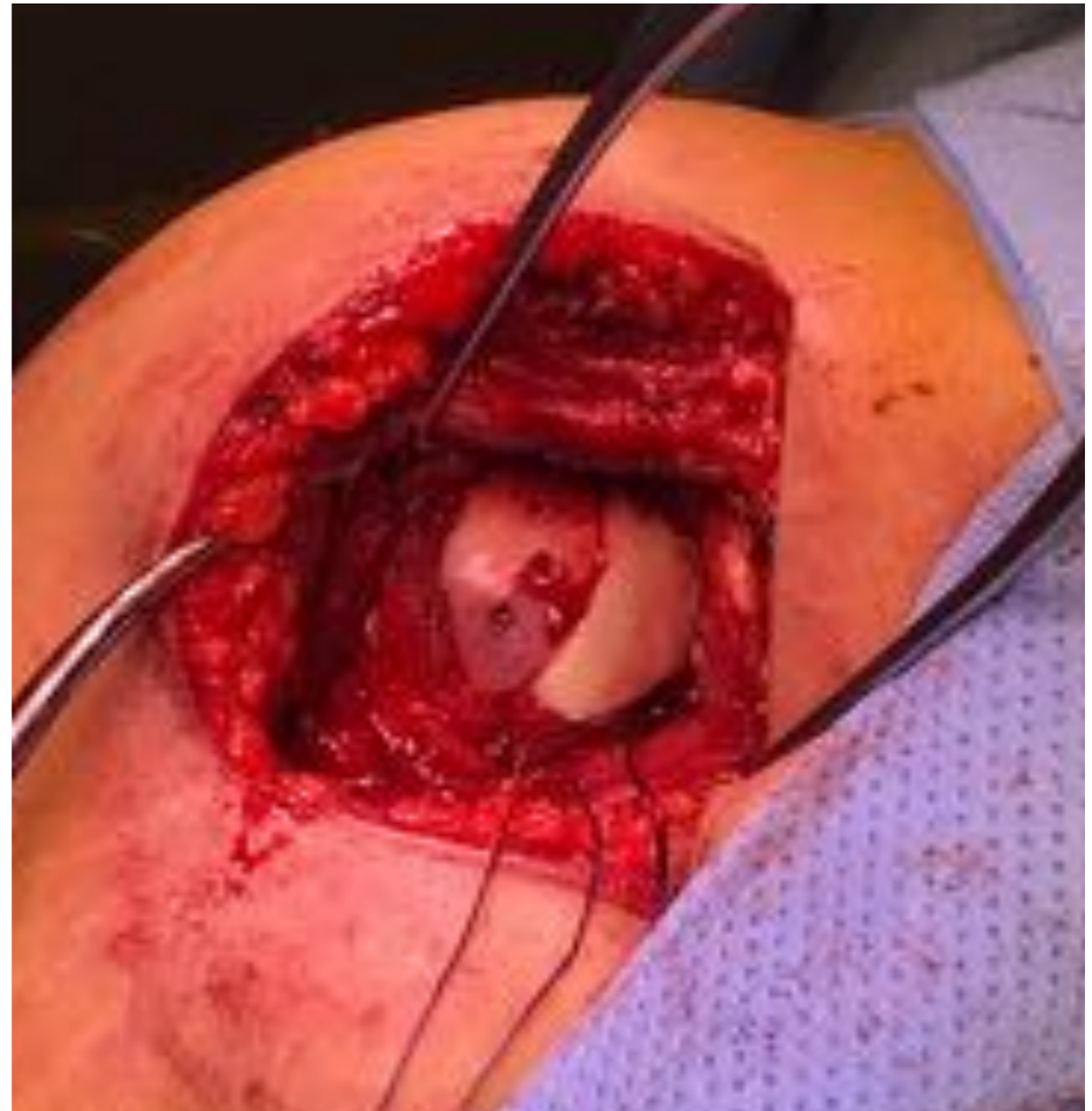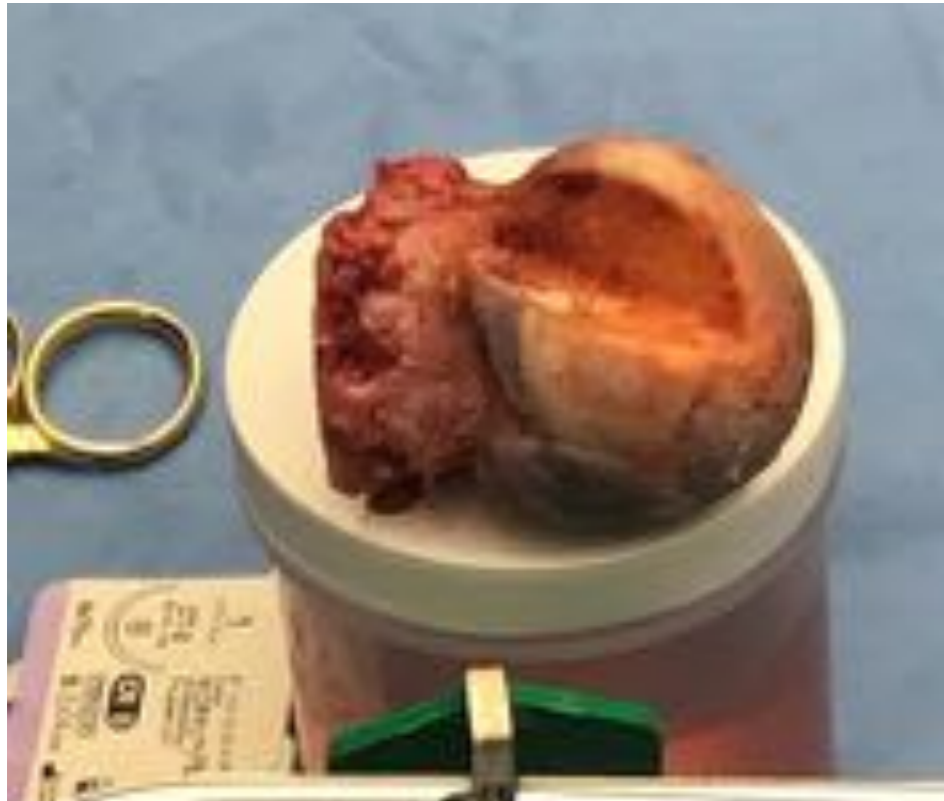
	ABER	Direct Trauma
Bankart	79%	33%
Benige Bankart	26%	11%
Posterior Labrum	11%	50%
SLAP	7%	35%
Partieel cuff leasie	32%	12%

Procedure	Return to Play (maanden)
SLAP	2.6
Bankart + SLAP	3
Posterior labrum + SLAP	4.1
Latarjet	4.6
Cuff repair	4.8
Bankart + posterior + SLAP	5.5

Status na repositie?



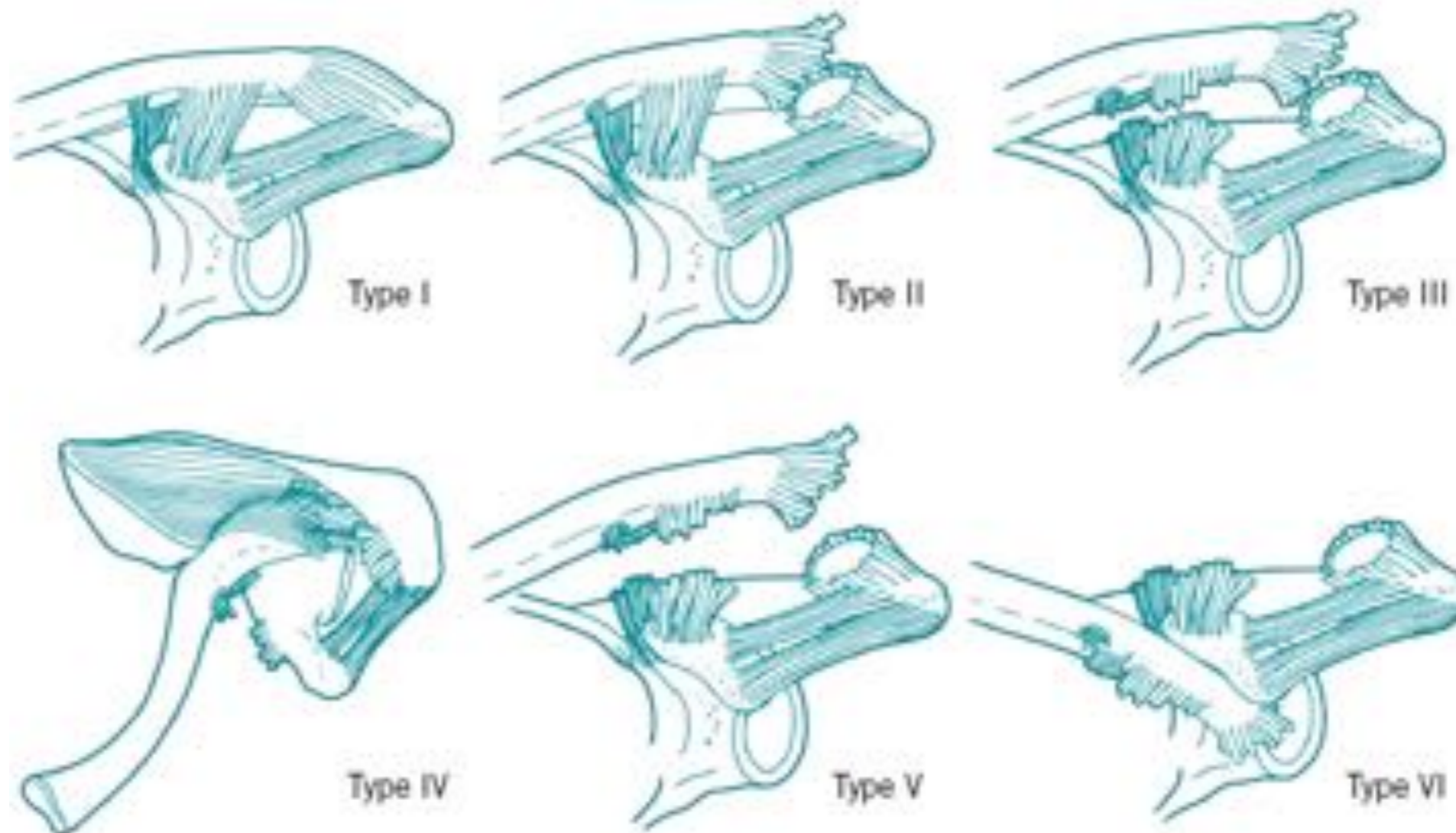
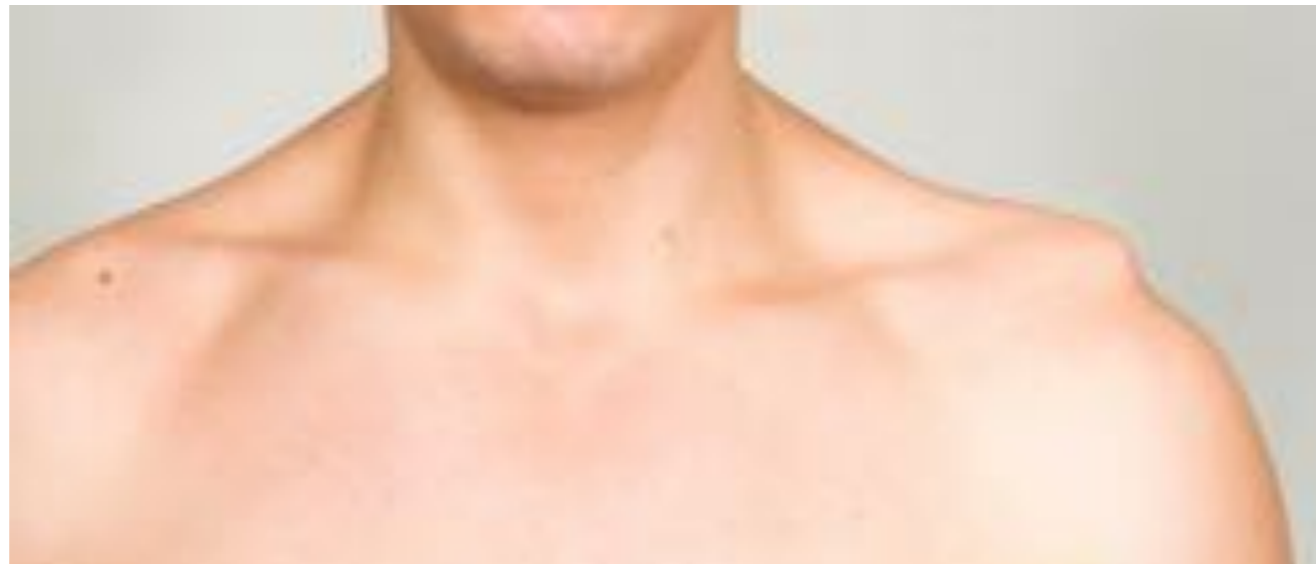Reconstructie met Allograft heupkop



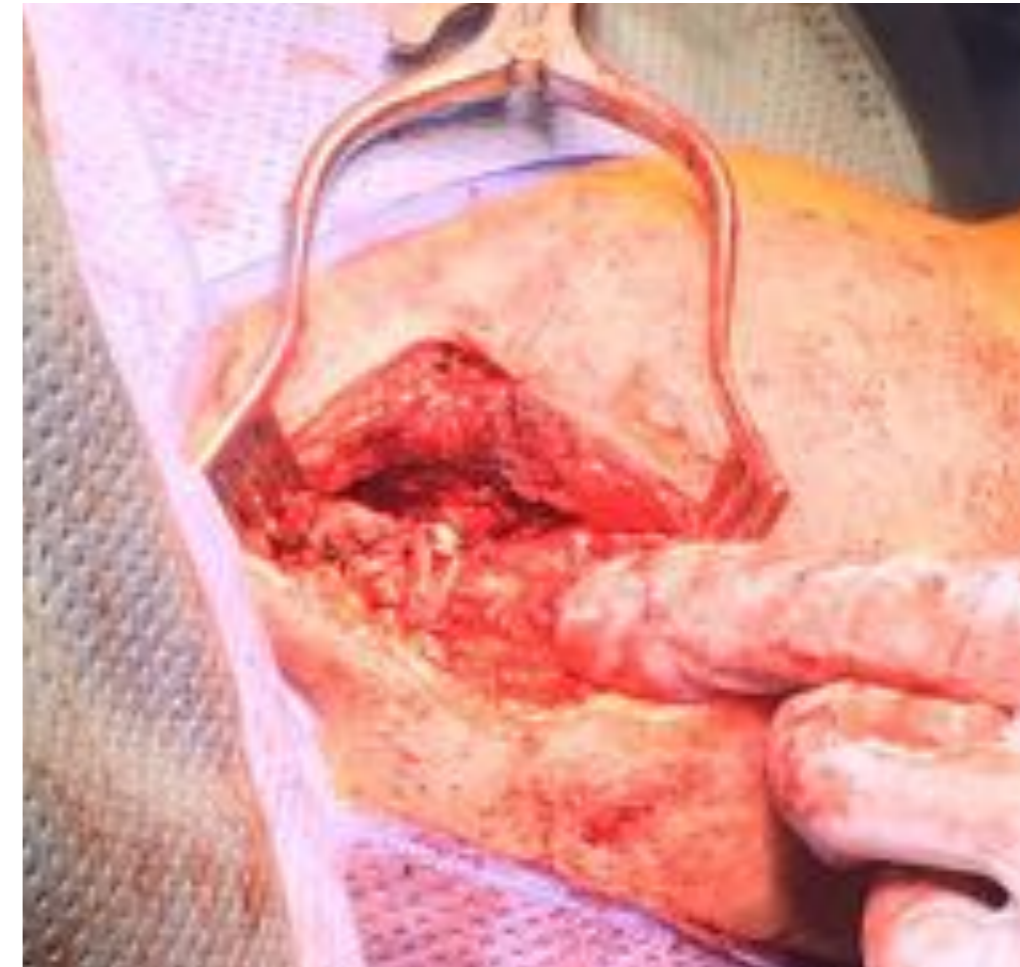
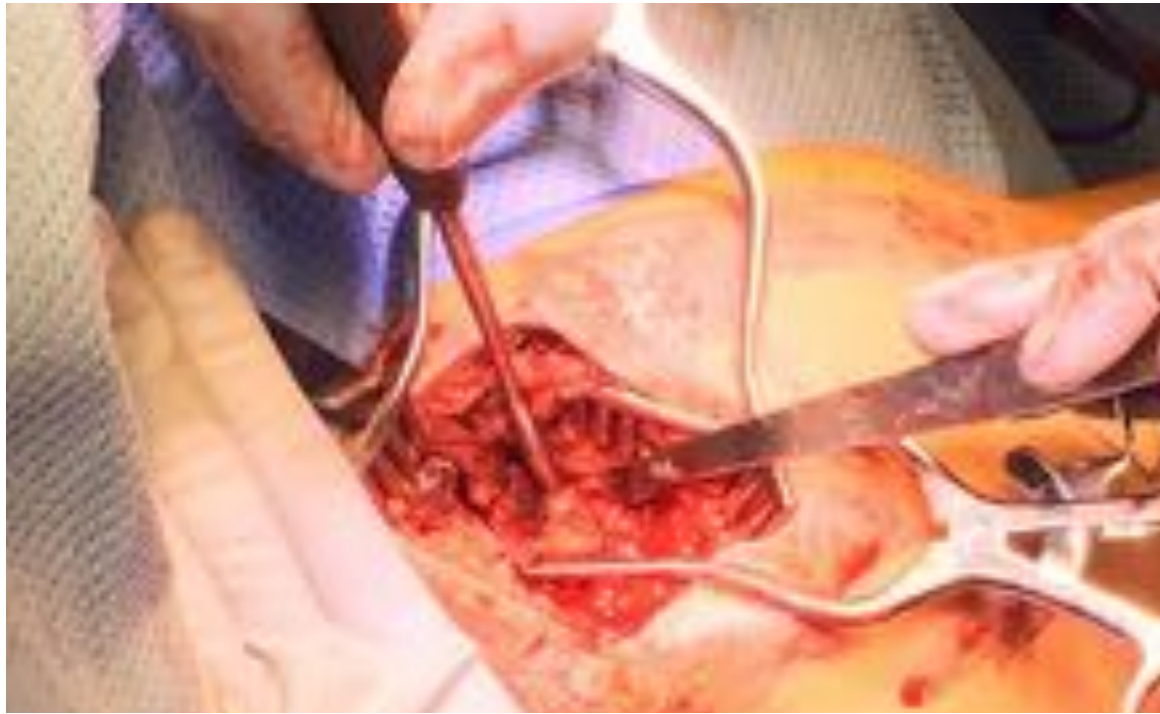
Wat gebeurt hier?

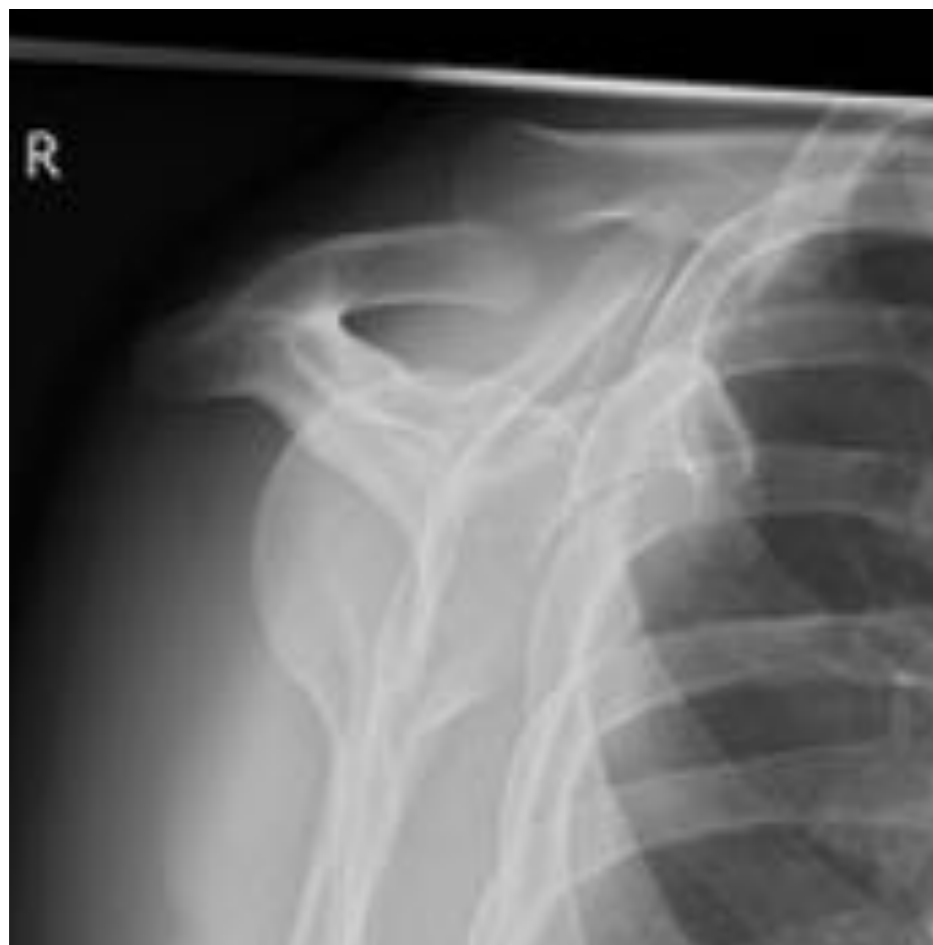

AC luxatie Rockwood classificatie

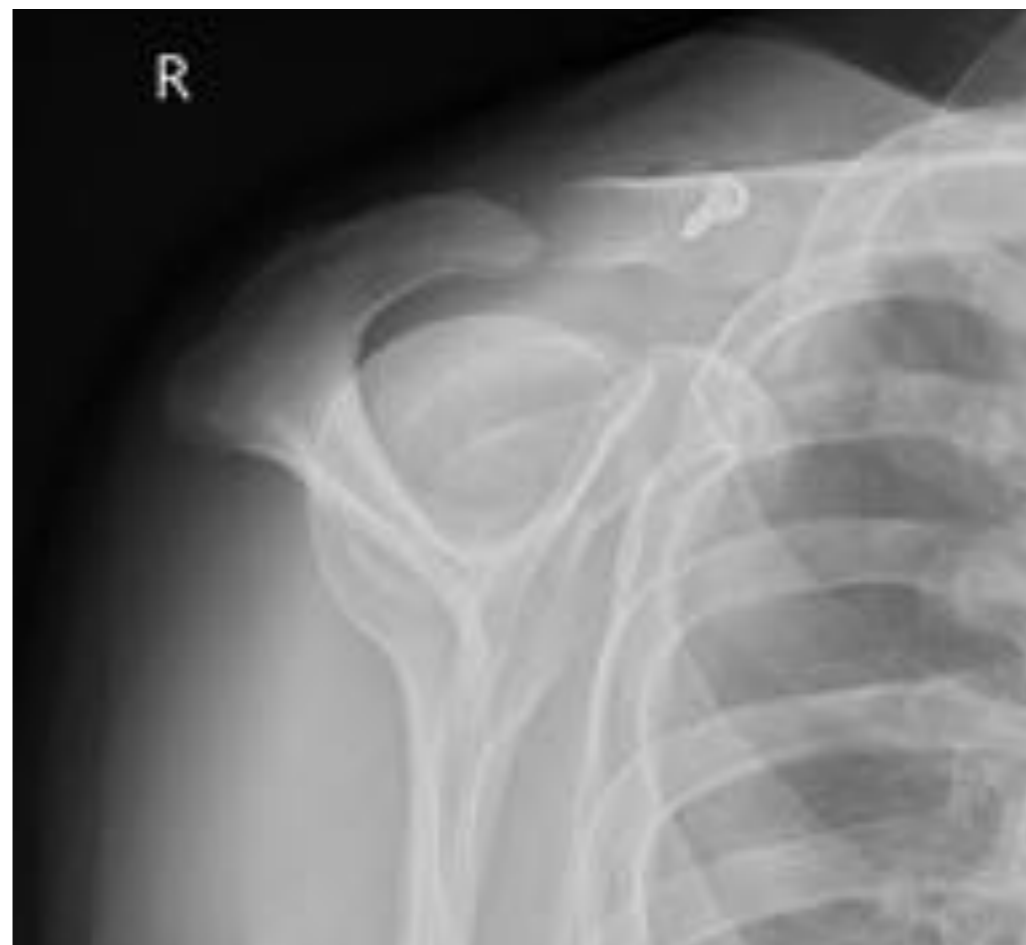

AC reconstructie



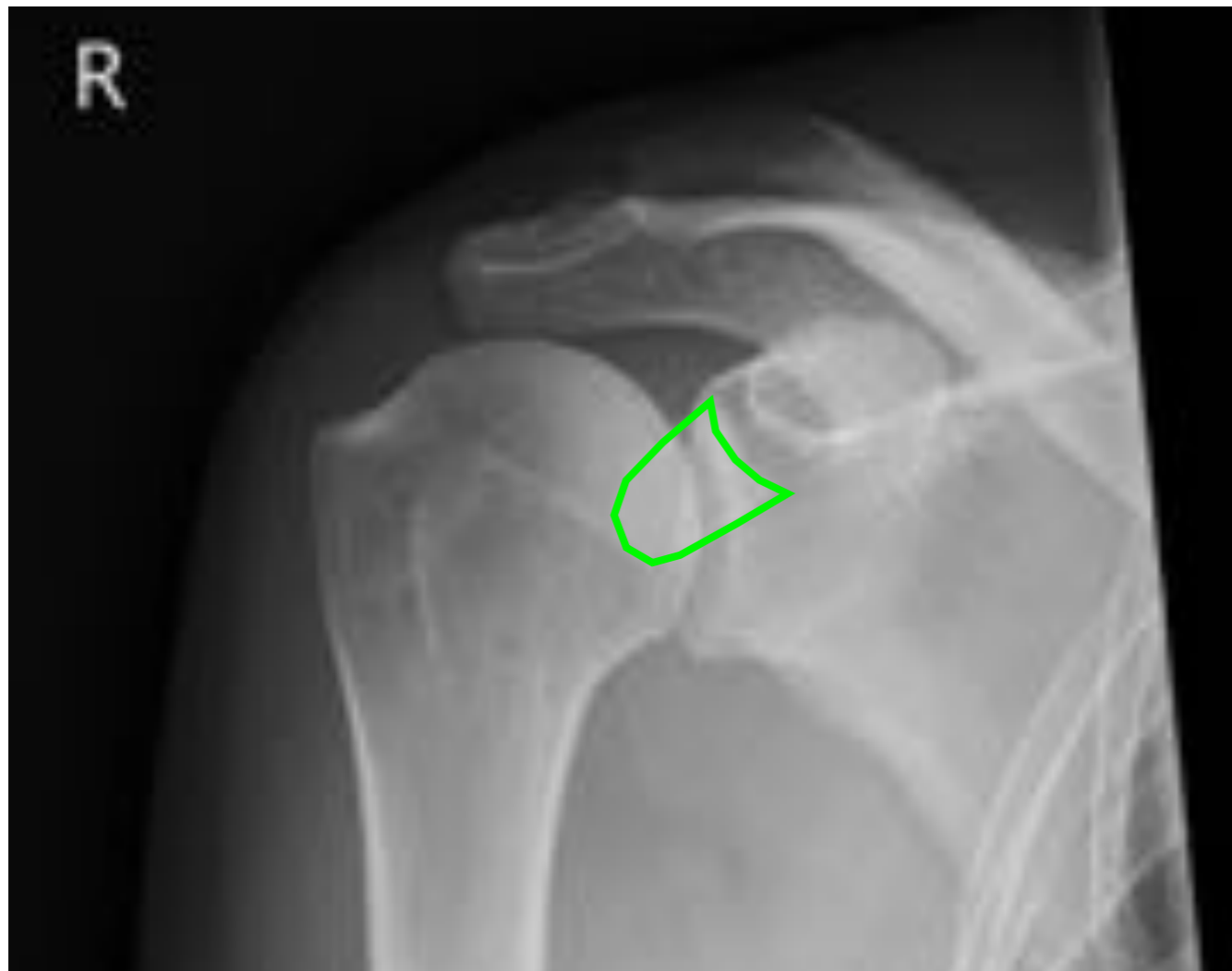

Pre-op

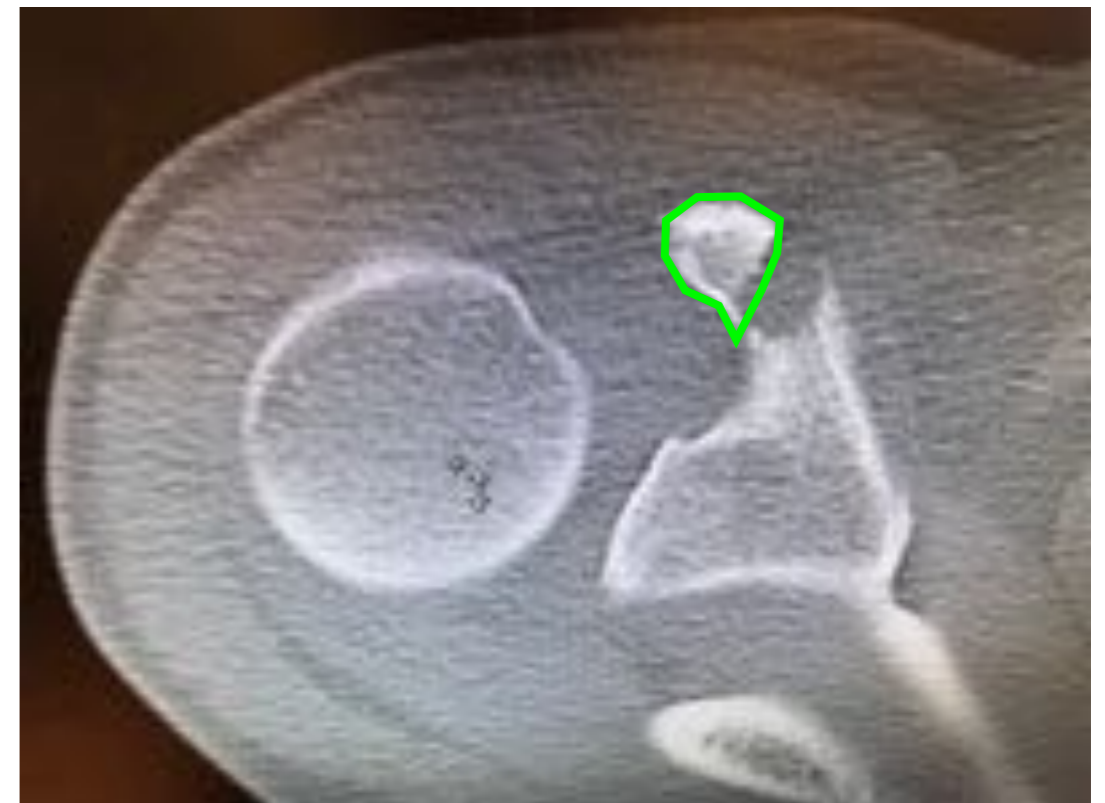

Post-op

Val direct op schouder.
Goede ROM; stabiel; erg pijnlijk!!



Wie ziet het?



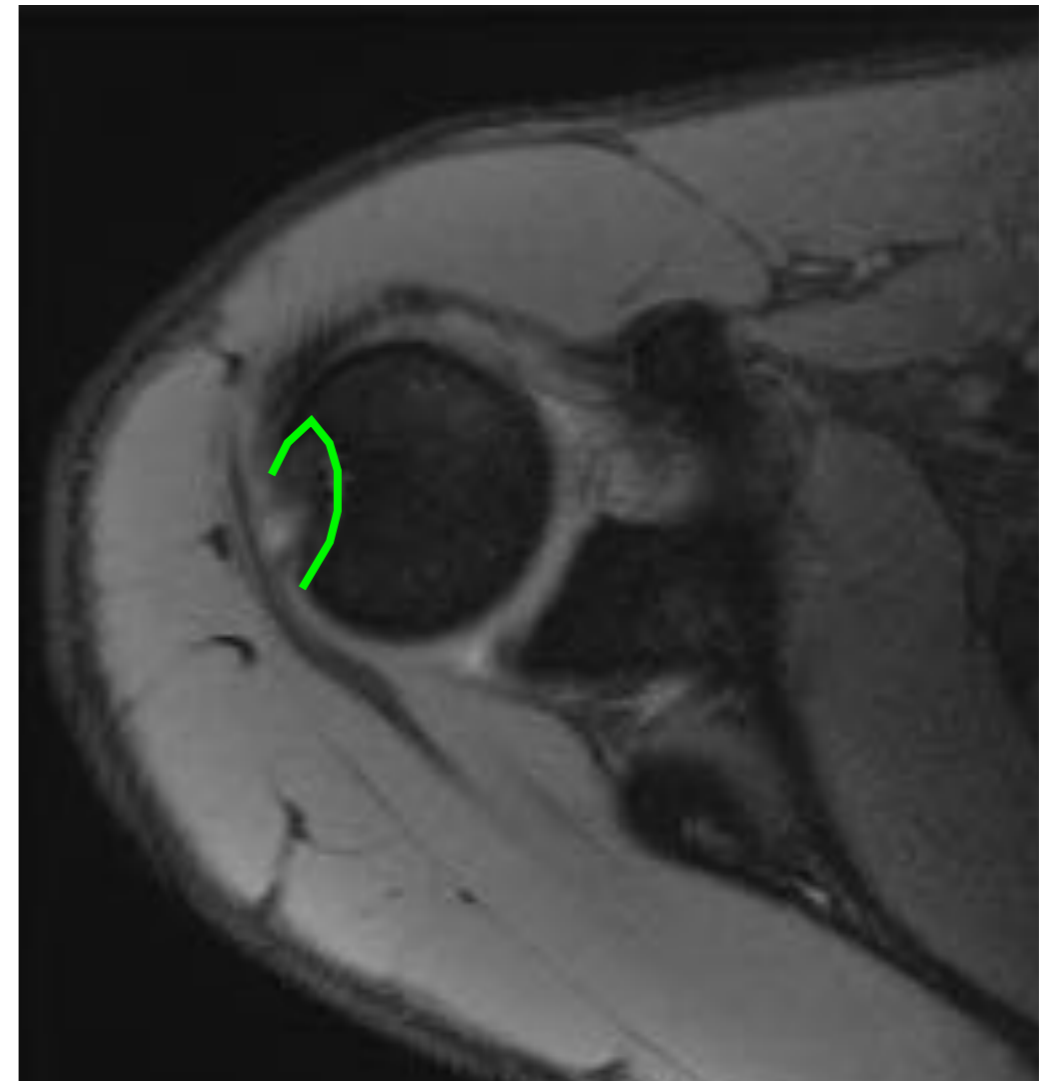
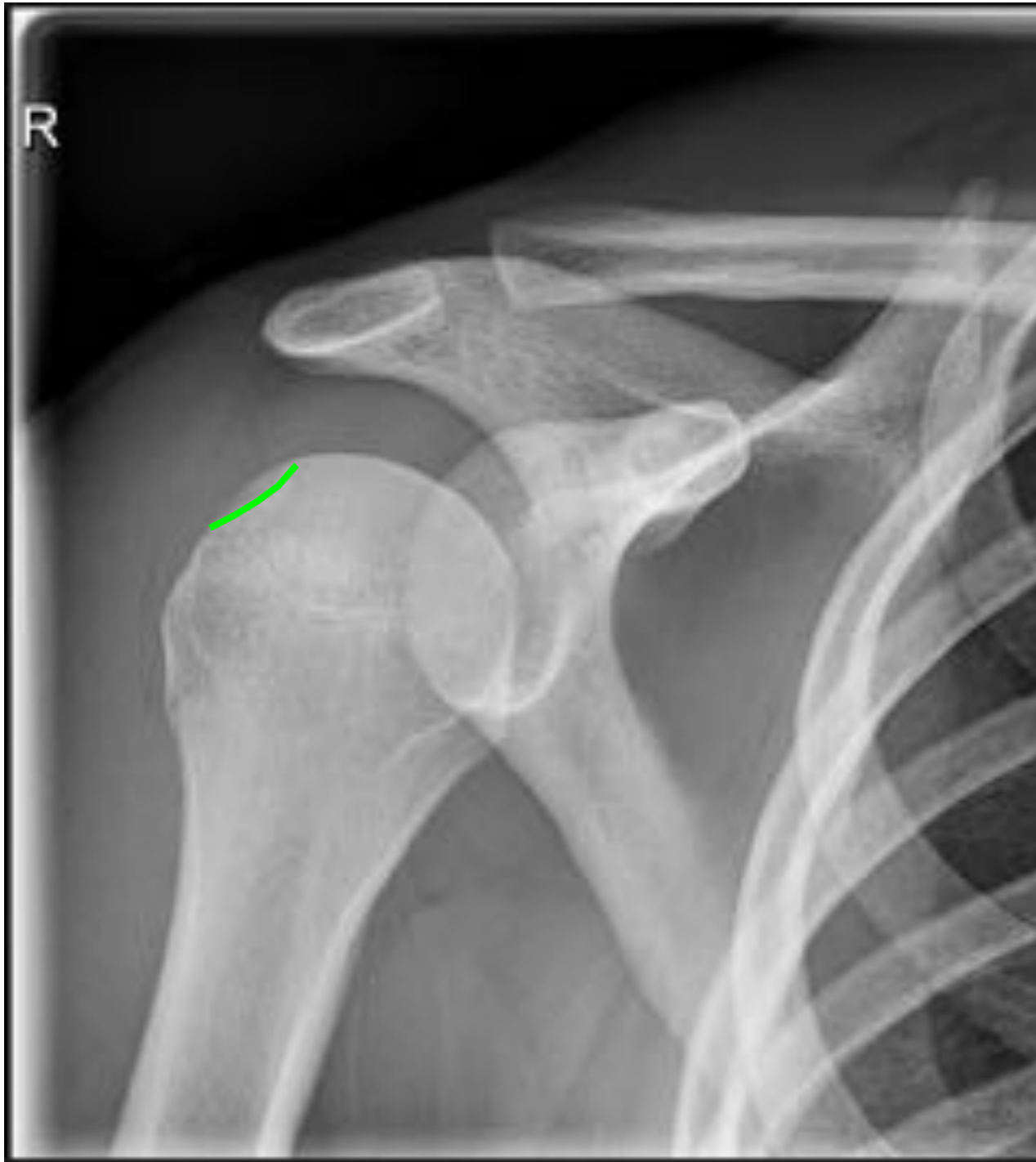Coracoidfractuur

Casus
Topklasse voetballer 19 jaar

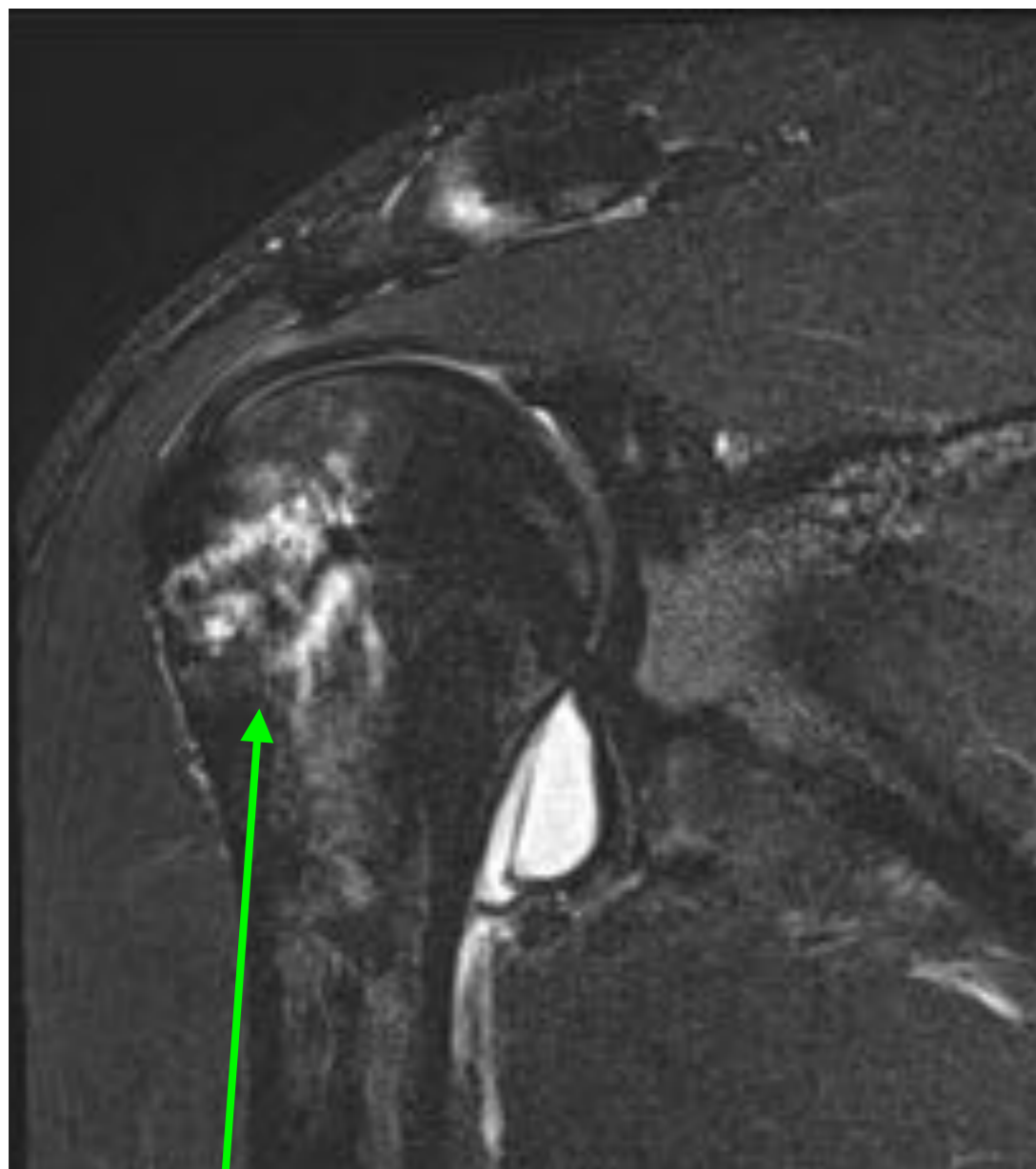Video

Eerste luxatie op 5 oktober 2015

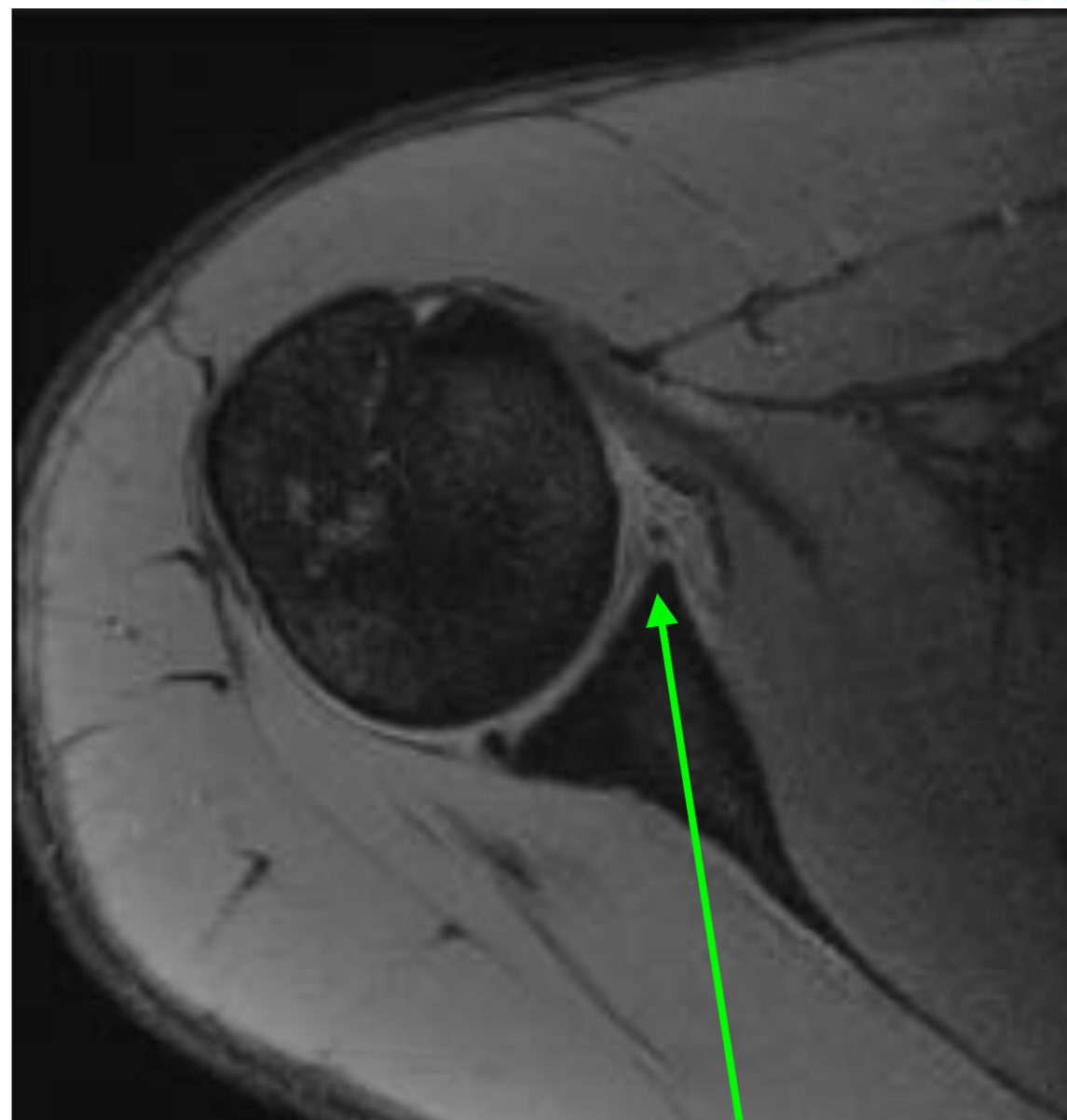
X-foto



Afwijkend?



Oedeem kop



Labrumscheur
12-5 uur

Recidief risico

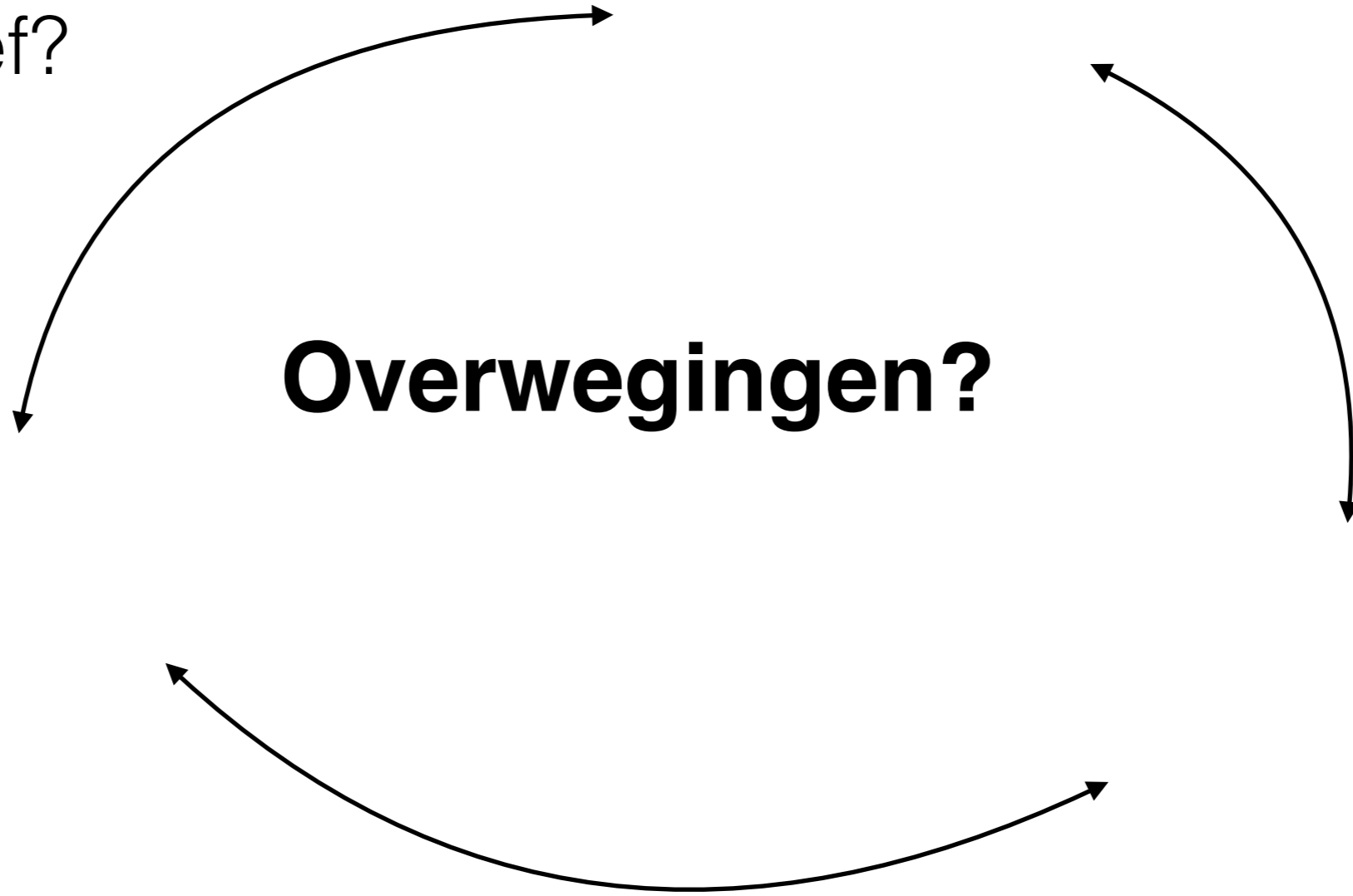
37-90% *Review by Watson et al. Sports Health 2016*

Conservatief?

Operatie?

Overwegingen?

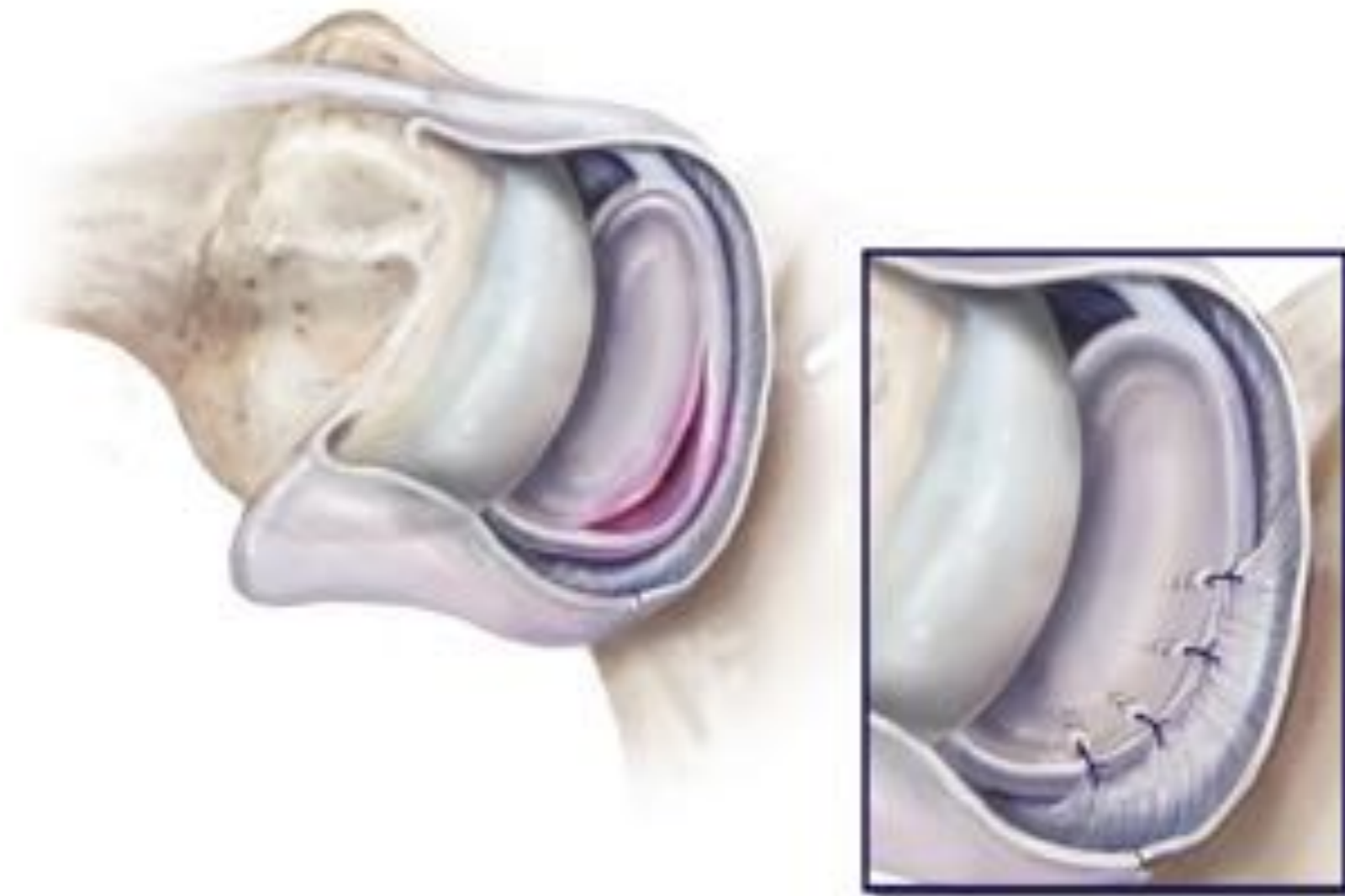
Timing?



Scopie schouder op 16 oktober 2015

Bevindingen:

Impressie: grommigheid
Caput humeri: Mene van 100-120% impressie
Glenoid aan anterieur inferieur type: chronische leese passend bij Bankart lesion
Brachiale trochanter: intact
Labrum anterieur: lig. ter van I-II
Labrum posterieur: goed
ACJ: intact
ACJ: partiale ruptuur passend bij acute Bankart
LACJ: intact
HACJ: lesion enige spreiding (kapitaal) van humerale type: geen tekenen bijgevoegde HACJ
Subscapularis: intact
Achilles: pijnlijk, goed functioneren
Rotator cuff: intact



Verrichting: scopische Bankart repair met 3 ankers

Nabehandeling


4 weken sling

Direct hand-, pols- en elleboogoefeningen

Na 2 weken circumductie

Na 4 weken geleid actief oefenen

OK: 16 oktober 2015



RtP: 4 februari 2016

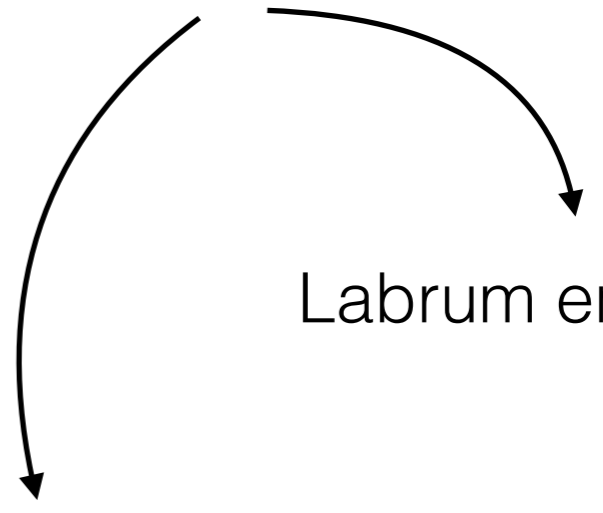
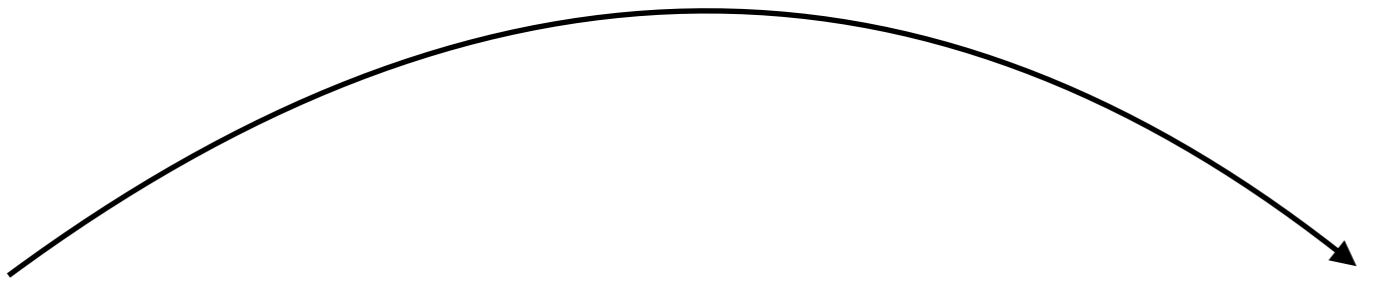
Anatomie

Specifieke letsels

Labrum en kapsel

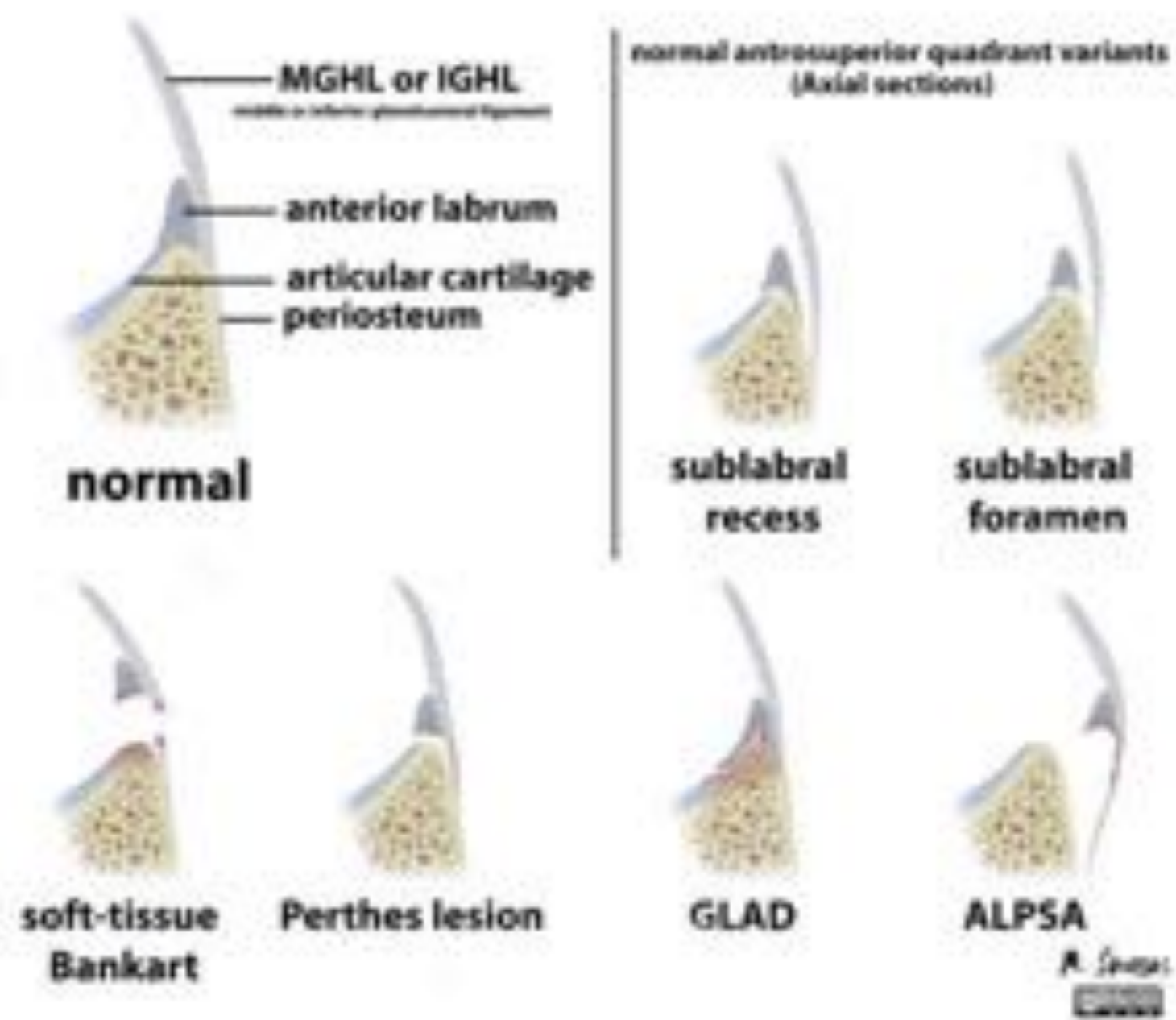
Minder voorkomende letsels

Casus



Vragen

Glenoid labrum tears



Engaging (off-track) Hill-Sachs Impression

